

CLINICAL VIGNETTE

Pheochromocytoma: A Case Report and Review of Clinical Presentation, Diagnosis, and Management

Neha Agarwal, M.D., and Gan Xon Ng, M.D.

Case Presentation

A 34-year-old woman presented to the Emergency Department with acute onset headache, shortness of breath, and chest tightness with anxiety. She reported a persistent headache and elevated blood pressure of 190/107, associated with a cough productive of pink-tinged sputum, shortness of breath, non-radiating chest pain, and sudden onset orthopnea associated with PND. She denied lower extremity swelling, palpitations, tremors, or sweating. Review of systems was notable for fatigue, unintentional weight loss, insomnia, and intermittent headaches and diplopia.

The patient had a past medical history significant for hypertension, hypothyroidism, hyperparathyroidism, hypertrophic cardiomyopathy, right adrenal mass found incidentally on a CT scan 3 years ago, and ESRD secondary to focal segmental glomerulonephritis s/p 3 renal transplants. Additional surgical history was notable for mechanical mitral valve replacement.

On presentation, the patient was afebrile with a blood pressure of 93/54 and pulse 78. Cardiac exam revealed a diastolic decrescendo murmur best heard at the right upper sternal border but showed no peripheral edema or JVD. Pulmonary exam was notable for bibasilar crackles.

Laboratory studies were remarkable for WBC 17.94 and BNP 1031 with normal troponin. EKG showed no evidence of acute or dynamic changes concerning for myocardial ischemia or infarct.

The patient's dyspnea was treated with furosemide and supplemental oxygen. Empiric antibiotics were started for treatment of endocarditis given her profound leukocytosis in the setting of a mechanical heart valve. Her leukocytosis subsequently resolved and a TEE was performed to rule out endocarditis. However, the patient continued to have multiple intermittent episodes of elevated blood pressures in the 200s/100s accompanied by headache, tachycardia, and anxiety. Her history of an adrenal mass previously seen on CT coupled with her symptoms raised the suspicion of a pheochromocytoma. A CT adrenal protocol (Figure 1) revealed a well-circumscribed heterogeneous right-sided adrenal mass. Both plasma free metanephrines and urinary fractionated metanephrines were elevated.

Plasma

- Metanephrines, Free 425 (nl <57)
- Normetanephrine, Free 528 (nl <148)
- Total, Free Metanephrines+normetanephrines 953 (nl <205)

Urine 24 hours

- Metanephrines 1150 (nl <190)
- Normetanephrines 1023 (nl <482)
- Metanephrines total 2173 (nl < 595)

The abnormally high serum and urine metanephrines combined with the CT findings solidified the diagnosis of a pheochromocytoma.

Finally, a PET study using ¹⁸F-FDOPA (3,4-dihydroxy-6-(18)F-fluoro-phenylalanine positron emission tomography) was ordered to assess the potential of metastatic disease. PET demonstrated an intensely ¹⁸F-FDOPA avid mass arising only from the right adrenal gland (Figure 2).

Discussion

A pheochromocytoma is a rare neuroendocrine neoplasm of chromaffin cells, occurring in approximately 0.95 per 100,000 persons.¹ Though 80-85% neoplasms have been described within the adrenal medulla, 15-20% are found in the sympathetic nervous system ganglia and are referred to as paragangliomas, PPGs. While PPGs in the abdomen secrete high levels of catecholamines, most paragangliomas found in the head and neck are nonfunctional.² Recent advances in genome sequencing have demonstrated that approximately 35% of these chromaffin cell neoplasms are hereditary.³

Pheochromocytomas have been described in all ages. Peak incidence occurs in the fourth and fifth decades in sporadic cases and earlier in associated hereditary conditions.^{4,5} Though 20-30% of pheochromocytoma cases are detected incidentally in asymptomatic patients, approximately 1 in 5000 patients evaluated for hypertension are found to have a pheochromocytoma.³ However, autopsy studies reveal a prevalence of 0.05%, indicating many tumors are undiagnosed and may contribute to premature mortality.⁶⁻⁸

Clinical Manifestations

Paroxysmal hypertension is the most common symptom. Patients often also present with bouts of sweating, palpitations, anxiety, headaches, tachycardia, and tremors. Metabolic derangements such as lactic acidosis, weight loss, and hyperglycemia are found in one in three patients secondary to catecholamine excess.⁹ Without treatment, patients face an increased rate of cardiovascular morbidity due to catecholamine-induced malignant hypertension, stroke, heart failure, and fatal arrhythmias.¹⁰ Metastatic disease is often fatal.

Diagnosis

Biochemical testing is indicated in symptomatic patients, those with an adrenal incidentaloma, or genetic predispositions. Initial screening evaluation should include measurements of plasma free or urinary fractionated metanephrines,^{11,12} with an appropriate consideration of modulatory factors such as posture-associated increases in metanephrines, antidepressant medications, dietary factors, and physiological stress with illness.^{13,14}

Positive laboratory results should be followed by an attempt to localize the tumor with CT for initial imaging, followed by a MRI for assessment of metastatic disease. If results are inconclusive, ¹²³I-MIBG (metaiodobenzylguanidine) scintigraph functional imaging can locate tumor cells with a high specificity of 83%³ but can be confounded by concomitant medication administration.

In these patients, ¹⁸F-FDOPA PET is a reliable functional imaging modality to confirm diagnosis and evaluate for smaller metastases.¹⁵ Prior to definitive management, all patients with a significant family history or patients younger than the age of 50 should undergo genetic testing to evaluate for Von-Hippel-Lindau, neurofibromatosis type 1, and multiple endocrine neoplasia type 2 or succinate dehydrogenase syndromes.¹⁶

Treatment

Definitive management of pheochromocytomas includes complete adrenalectomy or partial excision in patients with bilateral or multifocal disease. Prior to surgery, patients must be pretreated with an alpha-blocker to prevent life-threatening complications during surgery including hypertensive crises, cardiac arrhythmias, pulmonary edema, and cardiac ischemia.¹⁷⁻¹⁹ No randomized control trials have been done to determine the most effective drug regimen.

A review of studies comparing phenoxybenzamine, a non-competitive alpha-blocker, to doxazosin, a competitive alpha-blocker showed no superiority between these two traditional options.²⁰ However, a non-competitive blockade with phenoxybenzamine has been shown to provide better intraoperative blood pressure control as it avoids drug displacement from adenoreceptors. This extended blockade, however, results in significant postoperative hypotension. Blockade usually lasts 10-14 days before patients undergo surgery.

Laparoscopic or robotic partial adrenalectomy are preferred compared to open surgery due to decreased morbidity.²¹⁻²³ Prognosis after surgical removal is excellent, although hypertension persists in 50% of patients.²⁴ Patients should be followed every year for 10 years after surgery given a recurrence rate of 17%.²⁵

Outcome of the Patient

The patient underwent a 14-day phenoxybenzamine blockade and laparoscopic adrenalectomy. Post-operatively the patient remained hypotensive and required pressure support for 24 hours. She subsequently recovered and was discharged home with annual endocrine follow-up.

Figures

Figure 1: CT Abdomen without and with contrast confirmed a focal soft tissue mass measuring 3x1.7cm with no evidence of extramedullary structures.

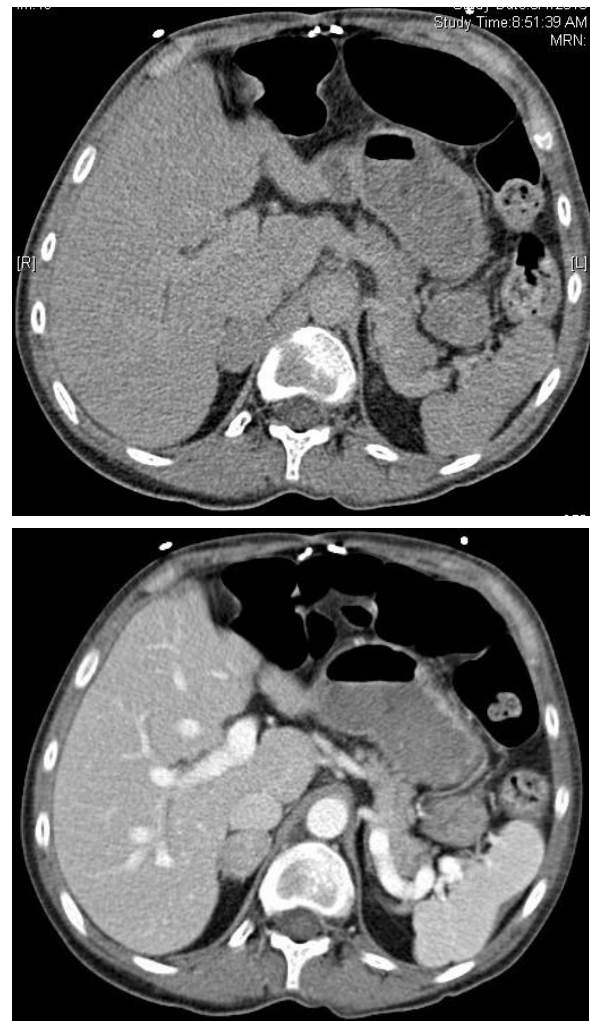
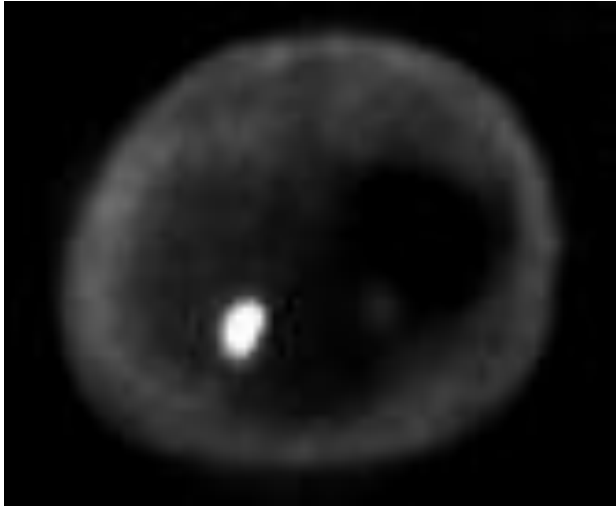


Figure 2: 18F-FDOPA PET/CT demonstrates an intensely ¹⁸F-FDOPA mass arising from the right adrenal gland, compatible with pheochromocytoma.



REFERENCES

1. **Beard CM, Sheps SG, Kurland LT, Carney JA, Lie JT.** Occurrence of pheochromocytoma in Rochester, Minnesota, 1950 through 1979. *Mayo Clin Proc.* 1983 Dec;58(12):802-4. PubMed PMID: 6645626.
2. **Lenders JW, Eisenhofer G, Mannelli M, Pacak K.** Phaeochromocytoma. *Lancet.* 2005 Aug 20-26;366(9486):665-75. Review. PubMed PMID: 16112304.
3. **Shuch B, Ricketts CJ, Metwalli AR, Pacak K, Linehan WM.** The genetic basis of pheochromocytoma and paraganglioma: implications for management. *Urology.* 2014 Jun;83(6):1225-32. doi: 10.1016/j.urology.2014.01.007. Epub 2014 Mar 15. Review. PubMed PMID: 24642075; PubMed Central PMCID: PMC4572836.
4. **O'Riordain DS, Young WF Jr, Grant CS, Carney JA, van Heerden JA.** Clinical spectrum and outcome of functional extraadrenal paraganglioma. *World J Surg.* 1996 Sep;20(7):916-21; discussion 922. PubMed PMID: 8678971.
5. **Neumann HP, Berger DP, Sigmund G, Blum U, Schmidt D, Parmer RJ, Volk B, Kirste G.** Pheochromocytomas, multiple endocrine neoplasia type 2, and von Hippel-Lindau disease. *N Engl J Med.* 1993 Nov 18;329(21):1531-8. Erratum in: *N Engl J Med* 1994 Dec 1;331(22):1535. PubMed PMID: 8105382.
6. **Platts JK, Drew PJ, Harvey JN.** Death from phaeochromocytoma: lessons from a post-mortem survey. *J R Coll Physicians Lond.* 1995 Jul-Aug;29(4):299-306. PubMed PMID: 7473324.
7. **Lo CY, Lam KY, Wat MS, Lam KS.** Adrenal pheochromocytoma remains a frequently overlooked diagnosis. *Am J Surg.* 2000 Mar;179(3):212-5. PubMed PMID: 10827323.
8. **McNeil AR, Blok BH, Koelmeyer TD, Burke MP, Hilton JM.** Phaeochromocytomas discovered during coronial autopsies in Sydney, Melbourne and Auckland. *Aust N Z J Med.* 2000 Dec;30(6):648-52. PubMed PMID: 11198571.
9. **La Batide-Alanore A, Chatellier G, Plouin PF.** Diabetes as a marker of pheochromocytoma in hypertensive patients. *J Hypertens.* 2003 Sep;21(9):1703-7. PubMed PMID: 12923403.
10. **Pacak K, Linehan WM, Eisenhofer G, Walther MM, Goldstein DS.** Recent advances in genetics, diagnosis, localization, and treatment of pheochromocytoma. *Ann Intern Med.* 2001 Feb 20;134(4):315-29. Review. PubMed PMID: 11182843.
11. **Lenders JW, Duh QY, Eisenhofer G, Gimenez-Roqueplo AP, Grebe SK, Murad MH, Naruse M, Pacak K, Young WF Jr; Endocrine Society.** Pheochromocytoma and paraganglioma: an endocrine society clinical practice guideline. *J Clin Endocrinol Metab.* 2014 Jun;99(6):1915-42. doi: 10.1210/jc.2014-1498. PubMed PMID: 24893135.
12. **Eisenhofer G, Peitzsch M.** Laboratory evaluation of pheochromocytoma and paraganglioma. *Clin Chem.* 2014 Dec;60(12):1486-99. doi: 10.1373/clinchem.2014.224832. Epub 2014 Oct 20. Review. PubMed PMID: 25332315.
13. **Yu R, Wei M.** False positive test results for pheochromocytoma from 2000 to 2008. *Exp Clin Endocrinol Diabetes.* 2010 Oct;118(9):577-85. doi: 10.1055/s-0029-1237699. Epub 2009 Dec 8. PubMed PMID: 19998239.
14. **Leow MK, Loh KC, Kiat Kwek T, Ng PY.** Catecholamine and metanephrine excess in intracerebral haemorrhage: revisiting an obscure yet common "pseudophaeochromocytoma". *J Clin Pathol.* 2007 May;60(5):583-4. PubMed PMID: 17513524; PubMed Central PMCID: PMC1994550.
15. **Imani F, Agopian VG, Auerbach MS, Walter MA, Imani F, Benz MR, Dumont RA, Lai CK, Czernin JG, Yeh MW.** 18F-FDOPA PET and PET/CT accurately localize pheochromocytomas. *J Nucl Med.* 2009 Apr;50(4):513-9. doi: 10.2967/jnumed.108.058396. Epub 2009 Mar 16. PubMed PMID: 19289420.
16. **Bryant J, Farmer J, Kessler LJ, Townsend RR, Nathanson KL.** Pheochromocytoma: the expanding genetic differential diagnosis. *J Natl Cancer Inst.* 2003 Aug 20;95(16):1196-204. Review. PubMed PMID: 12928344.
17. **Kinney MA, Warner ME, vanHeerden JA, Horlocker TT, Young WF Jr, Schroeder DR, Maxson PM, Warner MA.** Perianesthetic risks and outcomes of pheochromocytoma and paraganglioma resection. *Anesth Analg.* 2000 Nov;91(5):1118-23. PubMed PMID: 11049893.
18. **Quezado ZN, Keiser HR, Parker MM.** Reversible myocardial depression after massive catecholamine release from a pheochromocytoma. *Crit Care Med.* 1992 Apr;20(4):549-51. PubMed PMID: 1559374.
19. **Tauzin-Fin P, Hilbert G, Krol-Houdek M, Gosse P, Maurette P.** Mydriasis and acute pulmonary oedema complicating laparoscopic removal of phaeochromocytoma. *Anaesth Intensive Care.* 1999 Dec;27(6):646-9. PubMed PMID: 10631422.
20. **van der Zee PA, de Boer A.** Pheochromocytoma: a review on preoperative treatment with

- phenoxybenzamine or doxazosin. *Neth J Med*. 2014 May;72(4):190-201. Review. PubMed PMID: 24829175.
21. **Asher KP, Gupta GN, Boris RS, Pinto PA, Linehan WM, Bratslavsky G.** Robot-assisted laparoscopic partial adrenalectomy for pheochromocytoma: the National Cancer Institute technique. *Eur Urol*. 2011 Jul;60(1):118-24. doi:10.1016/j.eururo.2011.03.046. Epub 2011 Apr 9. PubMed PMID: 21507561; PubMed Central PMCID: PMC3109214.
 22. **Boris RS, Gupta G, Linehan WM, Pinto PA, Bratslavsky G.** Robot-assisted laparoscopic partial adrenalectomy: initial experience. *Urology*. 2011 Apr;77(4):775-80. doi: 10.1016/j.urology.2010.07.501. Epub 2010 Dec 3. PubMed PMID: 21122898; PubMed Central PMCID: PMC3074102.
 23. **Conzo G, Musella M, Corcione F, De Palma M, Ferraro F, Palazzo A, Napolitano S, Milone M, Pasquali D, Sinisi AA, Colantuoni V, Santini L.** Laparoscopic adrenalectomy, a safe procedure for pheochromocytoma. A retrospective review of clinical series. *Int J Surg*. 2013;11(2):152-6. doi: 10.1016/j.ijssu.2012.12.007. Epub 2012 Dec 23. PubMed PMID: 23267853.
 24. **Plouin PF, Chatellier G, Fofol I, Corvol P.** Tumor recurrence and hypertension persistence after successful pheochromocytoma operation. *Hypertension*. 1997 May;29(5):1133-9. PubMed PMID: 9149678.
 25. **Amar L, Servais A, Gimenez-Roqueplo AP, Zinzindohoue F, Chatellier G, Plouin PF.** Year of diagnosis, features at presentation, and risk of recurrence in patients with pheochromocytoma or secreting paraganglioma. *J Clin Endocrinol Metab*. 2005 Apr;90(4):2110-6. Epub 2005 Jan 11. PubMed PMID: 15644401.

Submitted July 14, 2016