

CLINICAL VIGNETTE

Lung Herniation after Minimally Invasive Cardiac Surgery

May-Lin Wilgus, MD

Case Presentation

A 52-year old man with history of obesity (BMI 37), chronic atrial fibrillation, obstructive sleep apnea, hypertension, and diabetes was undergoing pre-operative clearance for rotator cuff surgery when he was found to have severe mitral regurgitation. Cardiac evaluation confirmed myxomatous degeneration of the mitral valve with severe mitral insufficiency, anterior leaf prolapse, and a dilated mitral valve annulus. He underwent minimally invasive robotic-assisted mitral repair and annuloplasty, via a right inframammary incision at the 4th intercostal space. He recovered well in the immediate post-operative period.

Four months post-operatively, he developed progressive right-sided pleuritic chest pain associated with dyspnea on exertion and at rest. He had cough with pink sputum and an episode of cough syncope. He had two hospital visits with normal chest radiographs, and symptoms did not respond to antimicrobial therapy for suspected respiratory infection. CT angiogram of the chest 2 months after symptoms developed revealed lung herniation at the right 3rd and 4th intercostal spaces [Figures 1 and 2], with focal mild peripheral fibrosis. Additional history was obtained from the patient, who reported intermittent uncomfortable bulging of the right anterior chest with coughing and sneezing. On exam, bulging of the right pectoral region could be elicited with cough and valsalva. The patient was diagnosed with a postoperative lung herniation.

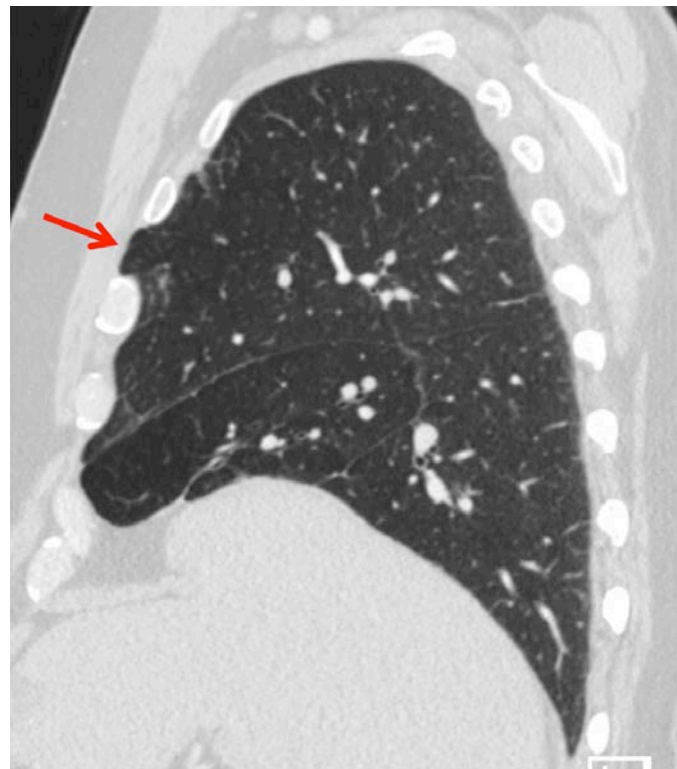


Figure 2.

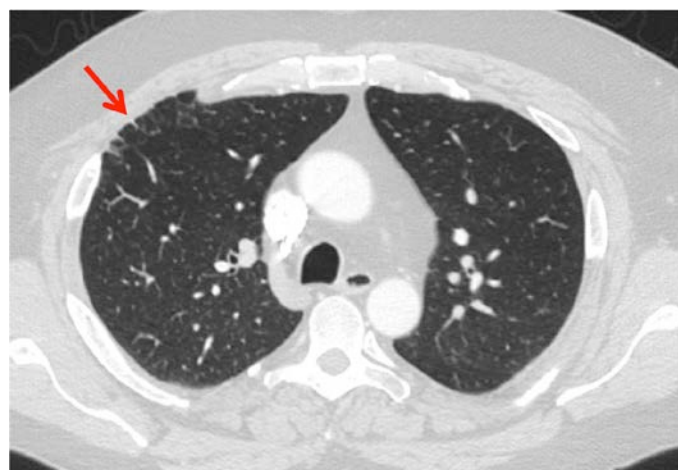


Figure 1.

Discussion

Lung herniation is an abnormal protrusion of lung tissue from the thorax. Lung herniation is uncommon, with fewer than 300 cases reported in 1994.¹ It is now seen with greater frequency as a complication of minimally invasive robotic and video-assisted cardiothoracic surgeries.² The first known description of lung herniation was made by Roland in 1499.³ Morel-Lavalee further classified the condition based on site and etiology in 1845.⁴ Maurer and Blades established the definition of lung herniation as “a protrusion of the pleural-covered lung beyond its normal boundaries through an abnormal opening in the thoracic enclosure”.^{5,6} As per Morel-Lavalee, lung herniation is classified by anatomic location (cervical, intercostal/thoracic, and diaphragmatic) and as congenital or acquired.^{4,7} Acquired hernias are further classified as post-operative, traumatic, pathologic, or spontaneous.⁷ Previous reports characterize 82% of lung hernias as acquired and 18% as congenital,⁸ however these data were collected prior to

modern operative techniques and may not represent current incidence.

Thoracic or intercostal hernias account for 65-83% of all lung hernias, while approximately 35% are cervical, and there are very few reported diaphragmatic hernias.⁹ Cervical lung herniation is most commonly acquired, usually in elderly individuals with chronic cough and emphysema, with weakened deep cervical fascia allowing lung protrusion into the supraclavicular space. There are rare reports of cervical lung herniation attributed to heavy weight lifting or playing wind instruments. Diaphragmatic lung herniation is extremely rare due to the high intra-abdominal pressure which favors herniation of abdominal contents into the thorax.⁷

Intercostal hernias occur due to decreased resistance of the chest wall and/or increased intrathoracic pressure. The most common location is in the parasternal region where there is no external intercostal muscle.⁷ Spontaneous lung herniation has been described due to cough and associated rib fracture in individuals with chronic obstructive pulmonary disease.⁹ Pathologic hernias may occur due to empyema necessitans.⁷ Currently, post-operative etiologies are probably the most common causes of intercostal lung herniation, specifically after minimally invasive robotic or video-assisted cardiothoracic approaches.² In minimally invasive mitral valve surgery, the skin incision is frequently smaller than the intercostal incision, and exposure may limit the ability to place pericostal sutures.⁶ Risk factors for lung herniation include morbid obesity and severe chronic obstructive pulmonary disease, or adverse wound healing from malnutrition, steroids, or diabetes.¹⁰ For patients undergoing minimally invasive thoracic surgery, it is important to limit strenuous activity during the post-operative period of chest healing.⁶

Lung herniation may present with pleuritic chest pain, cough, dyspnea, and a sensation of something “popping” out of the chest.^{6,10} The physical exam may reveal a palpable defect in the chest wall, or a thoracic bulge that increases in size with deep inspiration, cough, or Valsalva.^{7,10} Herniation can uncommonly result in incarceration and strangulation, leading to pain and hemoptysis.¹⁰ Traumatic or post-operative hernias can present years after the injury to the chest wall.² Lung herniation precipitated by positive pressure ventilation in a patient with remote thoracotomy has been described.¹¹ Rarely, lung herniation may present with life-threatening complications: hemothorax,^{12,13} or pneumomediastinum and tension pneumothorax.¹⁴

Lung herniation can easily be missed on plain film unless the hernia is perpendicular to the x-ray beam.⁷ CT is more sensitive for the detection of lung herniation, and can also characterize the dimensions of the hernia, and any associated pleural or lung parenchymal pathology.⁷ CT imaging during a valsalva maneuver can depict more obvious radiographic changes of lung herniation. Although unlikely to be performed given the availability of CT, xenon ventilation scanning of lung

herniation shows delayed filling and clearing of the radio-nuclide from the hernia.⁷

Indications for lung hernia repair include large hernia size, pain, recurrent respiratory infections, lung tissue incarceration, and hypoventilation.⁶ Smaller defects increase the risk of incarceration.² Asymptomatic lung hernias do not require repair,¹⁰ although sometimes repair for cosmetic reasons is justified.¹⁵ When repair is warranted, it can be performed with mesh⁶ or approximation of the ribs.² Skin grafts or muscle flaps are necessary only if soft tissue is lost.⁶

Due to persistent discomfort, this patient was taken for right chest wall repair with mesh. Post-repair he had resolution of pain, dyspnea, and cough.

REFERENCES

1. **Sonett JR, O'Shea MA, Caushaj PF, Kulkarni MG, Sandstrom SH.** Hernia of the lung: case report and literature review. *Ir J Med Sci.* 1994 Sep;163(9):410-2. Review. PubMed PMID: 7982766.
2. **Weissberg D, Refaely Y.** Hernia of the lung. *Ann Thorac Surg.* 2002 Dec;74(6):1963-6. PubMed PMID: 12643381.
3. **Roland.** De pulmonibus sanaripot. In: Chavliac G, editor *Cirurgia.* Liber III (cap); p 144.
4. **Morel-Lavalee A.** Hernies du poumon. *Bull Mem Soc Chir Paris.* 1845;1:75-195.
5. **Maurer E, Blades B.** Hernia of the lung. *J Thorac Surg.* 1946 Apr;15:77-98. PubMed PMID: 21024624.
6. **Gouda H, Multz AS, Khan A, Rossoff LJ, Green LM, Graver D.** Lung hernia as a sequela to limited-access mitral valve surgery. *Tex Heart Inst J.* 2002;29(3):203-5. PubMed PMID: 12224724; PubMed Central PMCID: PMC124760.
7. **Bhalla M, Leitman BS, Forcade C, Stern E, Naidich DP, McCauley DI.** Lung hernia: radiographic features. *AJR Am J Roentgenol.* 1990 Jan;154(1):51-3. PubMed PMID: 2104725.
8. **Hiscoe DB, Digman GJ.** Types and incidence of lung hernias. *J Thorac Surg.* 1955 Sep;30(3):335-42. PubMed PMID: 13252678.
9. **Ross RT, Burnett CM.** Atraumatic lung hernia. *Ann Thorac Surg.* 1999 May;67(5):1496-7. PubMed PMID: 10355447.
10. **Temes RT, Talbot WA, Green DP, Wernly JA.** Herniation of the lung after video-assisted thoracic surgery. *Ann Thorac Surg.* 2001 Aug;72(2):606-7. PubMed PMID: 11515908.
11. **Puah SH, Tan Pei Sze C, Abisheganaden J.** Lung herniation after positive pressure ventilation. *Respir Med Case Rep.* 2016 Dec 18;20:61-63. doi:10.1016/j.rmcr.2016.12.003. eCollection 2017. PubMed PMID: 28053853; PubMed Central PMCID: PMC5198735.
12. **Schroeter T, Bittner H, Subramanian S, Hänsig M, Mohr F, Borger M.** Life-threatening hemothorax resulting from lung hernia after minimally invasive mitral valve surgery. *Thorac Cardiovasc Surg.* 2011 Jun;59(4):252-4.

doi:10.1055/s-0030-1250670. Epub 2011 Mar 21. PubMed PMID: 21425058.

13. **Emberger JS Jr, Racine L, Maheshwari V.** Lung hernia associated with hemothorax following cardiopulmonary resuscitation. *Respir Care.* 2011 Jul;56(7):1037-9. doi: 10.4187/respcare.01069. PubMed PMID: 21740728.
14. **Mizuguchi S, Kaji M, Yoshida T, Iwasaki T, Kamimori T, Fujiwara H.** Severe mediastinal emphysema and tension pneumothorax caused by cough-induced intercostal lung herniation. *Open J Thoracic Surg.* 2014;4:1-4.
15. **Weissberg D.** Lung hernia - a review. *Adv Clin Exp Med.* 2013 Sep-Oct;22(5):611-3. Review. PubMed PMID: 24285444.

Submitted July 1, 2018