

## CLINICAL VIGNETTE

---

# Squamous Cell Carcinoma of the Lung Presenting as an Anterior Mediastinal Mass

---

Stephanie Pham and Satya Patel, MD

A 58-year-old male presented to the emergency department with chest pain and new-onset tachycardia. Labs done earlier that day by his primary care provider revealed low hemoglobin (10 g/dL), elevated platelet count (704,000 platelets per  $\mu\text{L}$  of blood), and elevated alkaline phosphatase (114 IU/L). He otherwise was feeling well in his usual state of health. His past medical history was significant for left-sided chest wall pain and swelling for 2 months diagnosed as costochondritis, left shoulder pain for 4 months attributed to tennis injury, and diabetes mellitus diagnosed 4 months prior with a subsequent 20-pound weight loss attributed to dietary changes. He had no known allergies, and his only medications were acetaminophen and ibuprofen for pain. His family history was significant for breast cancer in his mother. The patient was a Vietnam war veteran with a smoking history of 2-3 cigarettes per day for over 20 years. On physical exam, the patient was tachycardic up to 110 bpm with a large, non-tender, asymmetric, firm, and immobile subcutaneous mass on the left chest wall. His exam was notable for cachexia, tachycardia, and digital clubbing. Electrocardiogram showed sinus tachycardia. A computed tomography angiogram (CTA) of his chest revealed a large left anterior mediastinal mass invading into manubrium, sternum, left sided vasculature, and possibly pericardium (Figure 1). He was admitted for expedited malignancy work-up and cardiac monitoring. Due to concern for possible pericardial invasion and malignant pericarditis, transesophageal echocardiogram (TTE) was obtained, showing trivial pericardial effusion. Thoracic surgery was also consulted and noted that surgical intervention was not appropriate at that time.

Tumor markers which included anti-acetylcholine receptor antibodies, AFP,  $\beta$ -hCG and LDH were negative. Positron emission tomography (PET) imaging was consistent with findings on CTA, with significant fluorodeoxyglucose (FDG) uptake in the sternum, left lung and chest wall as well as moderate uptake in the left supraclavicular lymph node suspicious for metastatic lymphadenopathy (Figure 2). The patient underwent an IR-guided mediastinal mass biopsy. His chest discomfort was stable and tachycardia had improved and he was discharged with outpatient hematology oncology follow-up. Results of the biopsy with immunohistochemical staining returned and showed squamous cell carcinoma of lung origin.

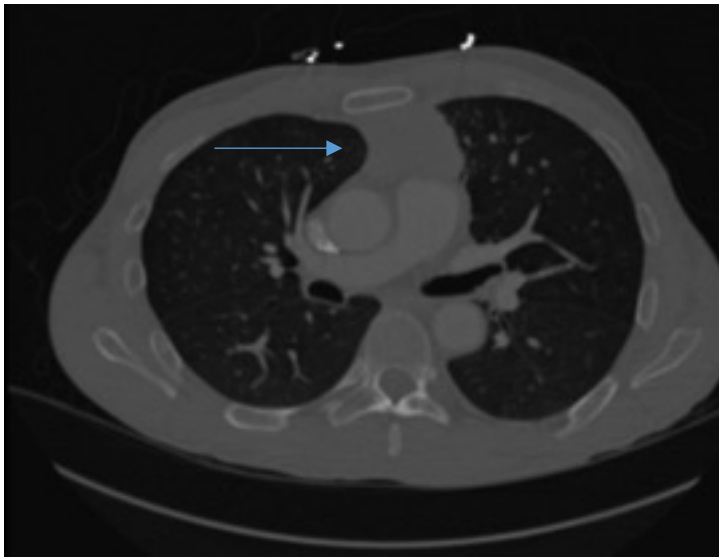
This clinical vignette highlights the importance of a comprehensive approach to the patient with an anterior mediastinal mass (AMM). The differential diagnosis of AMM is classically taught as the “4 Ts” – *terrible lymphoma*, *thymoma*, *teratoma or germ cell tumor*, and *thyroid mass*. However, in entirety, an anterior mediastinal mass may arise from any structure that normally resides in or passes through this space during development, and it may also be a result of metastases.<sup>1,2</sup> This case is an example of the latter.

A mediastinal mass may present with symptoms of mass effect (i.e., direct involvement or compression of adjacent structures) including cough (57%), dyspnea (46%), hemoptysis, stridor, dysphagia, hoarseness, hypotension due to cardiac compression or tamponade, pain and facial and/or upper extremity swelling due to vascular compression, and Horner syndrome due to sympathetic chain involvement.<sup>1,2</sup> In any case, AMM warrants timely diagnosis and accurate staging to allow for appropriate therapy.

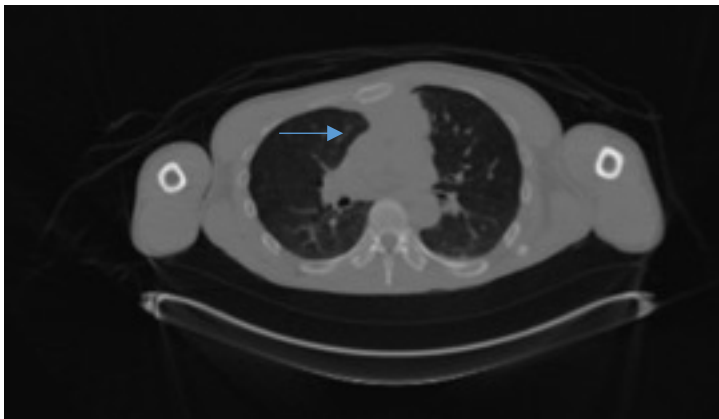
The role of TTE in evaluation of mediastinal masses is not well-defined, although it can be useful for evaluating cardiac structure and function, as well as distinguishing between pericardial and intracardiac tumors.<sup>3</sup> Contraindications to surgical resection of AMM include invasion of myocardium, great vessels or trachea. Pericardium is the most commonly invaded structure, followed by pleura, lungs, phrenic nerve and superior vena cava.<sup>4</sup> The potential for mediastinal masses to compress, obstruct or invade vital surrounding structures and cause respiratory compromise and/or hemodynamic decompensation poses great risks with surgery.<sup>3</sup>

Ultimately, the patient was diagnosed with stage IIIb NSCLC. Compared to stage IIIa (locally advanced tumor without mediastinal lymph node metastases), stage IIIb is considered to be unresectable.<sup>5</sup> The patient was treated with chemotherapy and radiation.

It is important for the clinician to maintain a broad differential diagnosis when approaching a patient with an anterior mediastinal mass. Given the risk of impacting adjacent vital structures, timely diagnosis of mediastinal masses and careful attention to providing expedited and appropriate treatment are paramount.



**Figure 1.** CT angiogram upon presentation to the emergency department, showing large left anterior mediastinal mass directly invading the posterior aspect of the manubrium and sternum and extending to the aortic arch and pulmonary trunk with possible invasion into pericardium.



**Figure 2.** PET/CT imaging during hospital admission showing a large anterior/superior mediastinal mass with intense FDG uptake and invasion to the sternum, left lung and chest wall.

## REFERENCES

1. **Su S, Colson YL.** Overview of benign and malignant mediastinal diseases. In: *Adult Chest Surgery*, 2nd ed, Sugarbaker DJ, Bueno R, Colson YL, et al (Eds), McGraw-Hill Education, New York 2015. p.1234.
2. **Aroor AR, Prakasha S R, Seshadri S, S T, Raghuraj U.** A study of clinical characteristics of mediastinal mass. *J Clin Diagn Res.* 2014 Feb;8(2):77-80. doi: 10.7860/JCDR/2014/7622.4013. Epub 2014 Feb 3. PubMed PMID: 24701488; PubMed Central PMCID: PMC3972605.
3. **Li WW, van Boven WJ, Annema JT, Eberl S, Klomp HM, de Mol BA.** Management of large mediastinal masses: surgical and anesthesiological considerations. *J Thorac Dis.* 2016 Mar;8(3):E175-84. doi: 10.21037/jtd.2016.02.55. Review. PubMed PMID:27076967; PubMed Central PMCID: PMC4805811.

4. **Ong CC, Teo LL.** Imaging of anterior mediastinal tumours. *Cancer Imaging.* 2012 Nov 2;12:506-15. doi: 10.1102/1470-7330.2012.0039. Review. PubMed PMID: 23131900; PubMed Central PMCID: PMC3490464.
5. **Park B, Cho JH, Kim HK, Choi YS, Zo JI, Shim YM, Kim J.** Long-term survival in locally advanced non-small cell lung cancer invading the great vessels and heart. *Thorac Cancer.* 2018 May;9(5):598-605. doi: 10.1111/1759-7714.12625. Epub 2018 Mar 30. PubMed PMID: 29602232; PubMed Central PMCID: PMC5928382.

Submitted March 6, 2019