

CLINICAL VIGNETTE

Fatal Case of Primary Hyperparathyroidism – Case Report and Review of Literature

Yi-Kong Keung, MD, FACP

Introduction

Fatal cases of hyperparathyroid crises have been reported as early as 1950s before parathyroid hormone (PTH) assay was available with autopsy confirmation of the diagnosis. In 1958, Hewson and Burlington reported a case of sudden death of a 38-year-old truck driver nine hours after admission for nausea, vomiting, lethargy and serum calcium 18.9 mg/dL. The parathyroid adenoma was confirmed at autopsy.¹ Hyperparathyroid crisis has been variously termed as symptomatic hyperparathyroidism, acute hyperparathyroidism, parathyroid storm, etc. in the past. During 1960-70s, 2.5% -6% cases of hyperparathyroidism presented as hyperparathyroid crises.^{2,3}

With advent of automated serum analysis, hyperparathyroidism usually presents as asymptomatic hypercalcemia with elevated intact PTH assay. Parathyroid ultrasound and sestamibi nuclear medicine scan can localize the parathyroid glands preoperatively. However, fatal cases of hyperparathyroidism continues to be reported after the millennium.^{2,4-13}

Case Presentation

A 64-year-old healthy non-smoker male presented to a community hospital emergency room with acute back pain for one week. Severe hypercalcemia and renal failure were noted prompting admission directly to the ICU. He had no significant past medical, surgical or family history. Physical examination was unremarkable except for right lower back tenderness. Labs were remarkable for WBC 14,900/ μ L, hemoglobin 13.8 gm/dL and platelets 351,000/ μ L, blood smear did not show any significant rouleaux formation. Elevated serum creatinine to 4.79 mg/dL, and serum calcium to 17.8 mg/dL; total protein 8 g/dL, albumin 3 g/dL, alkaline phosphatase 161 U/L, AST 31 U/L, ALT 49 U/L and total bilirubin was 0.2 mg/dL. LDH 349 U/L (normal 135-225), uric acid 3.7 mg/dL, ESR 22 ml/hr, lactic acid 1 mmol/L (normal 0.4 - 2). C-reactive protein was elevated to 22.83 mg/dL (normal 0 - 0.3). Antinuclear antibody and antinuclear cytoplasmic antibodies (proteinase-3 and myeloperoxidase antibodies) were negative. Angiotensin converting enzyme was 22 U/L (normal 9 - 67). Carcinoembryonic antigen and CA19-9 levels were normal. Serum protein electrophoresis and immunofixation revealed no evidence of monoclonal gammopathy. HIV antibody, HBsAg and HCV antibody were negative. Ultrasound of the kidneys showed increased echogenicity in both kidneys; and a 6 mm right lower pole echogenic focus possibly a renal stone without obstruction. Chest radiograph on admission was normal (Figure 1A & 1B).

Radiograph of lumbar spine showed mild to moderate degenerative changes of the spine.

He was started on rigorous hydration with normal saline and hemodialysis was instituted six hours after admission along with subcutaneous calcitonin 4 units/kg twice daily. The patient developed a low grade temperature of 100.1°F and chest radiograph on hospital day 2 showed bilateral patchy lower lung infiltrates and empiric piperacillin-tazobactam and vancomycin were started. For persistent hypercalcemia, the patient also received parateneal dexamethasone 10 mg intravenously and pamidronate 90 mg infusion 2 days after admission (Figure 2). On hospital day 2 the patient developed respiratory distress and required emergent intubation. Chest radiograph showed extensive bilateral lung infiltrates (Figure 1C & 1D). Antibiotics were empirically switched to levofloxacin, linezolid, meropenem and fluconazole. WBC increase to 51,000/ μ L and serum lactic acid increased to 4.6 mmol/L. Intravenous hydrocortisone 100mg every eight hours was started. He developed refractory hypotension requiring noradrenaline, neosynephrine and vasopressin infusion. The patient rapidly succumbed to sepsis, pneumonia and acute respiratory distress syndrome 76 hours after admission. Calcium decreased to 10.6 mg/dL on the day of death.

Intact parathyroid hormone (PTH) subsequently returned at 3,084 pg/ml (normal 14 - 64). C-terminal PTH-related peptide 17 pg/mL (normal 14-27) and total 25-hydroxy vitamin D 12 ng/ml (normal 30-100).

Discussion

Because of routine testing of serum calcium levels, the most common presentation of primary hyperparathyroidism is asymptomatic hypercalcemia. Hyperparathyroid crisis is quite rare in modern medical practice. When it occurs, hyperparathyroid crisis may be rapidly fatal due to severe hypercalcemia, acute renal failure and multiple organ failure as a result of metastatic calcification to various vital organs leading to cardiomyopathy, cardiac arrhythmia, myopathy of respiratory muscle, respiratory distress syndrome, etc.^{5,6,8,14}

Schenker & Kallner reported a 30-year-old female two weeks after childbirth who developed restlessness, bizarre behavior and lapsed into coma within 48 hours. Autopsy revealed primary chief cell hyperplasia of the parathyroid gland with

widespread metastatic calcification in the heart, lung, kidneys and blood vessels.² Love & Samuels reported a 43-year-old male who presented with nausea, vomiting, lethargy and generalized joint pain for six weeks, serum calcium level of 18.2 mg/dL and who died within 24 hours of admission. Autopsy confirmed parathyroid carcinoma and metastatic calcification in multiple organs.¹⁵ Keeling et al reported a 35-year-old female who presented with 4-day history of abdominal pain, nausea, vomiting, lethargy, serum calcium 30.5 mg/dl and serum creatinine 1.9 mg/dL. She received intravenous hydration, corticosteroid and mithramycin with calcium decreased to 14 mg/dL. However, she became anuric, hypotensive and died 12 hours after admission. Autopsy revealed a 2cm parathyroid adenoma and metastatic calcification in the heart, liver and kidneys.⁴

Our patient had serum calcium of 17.8 mg/dL and intact PTH level over 3,000 pg/mL which is diagnostic of primary hyperparathyroidism. Extremely high levels of PTH are ominous. Polo & Coen described a case very similar to this case. A 64-year-old white man was admitted for syncope and mental confusion, elevated serum creatinine of 3.7 mg/dL and severe hypercalcemia of 16.4 mg/dL. The PTH level was 1,166 pg/mL. Intravenous hydration, furosemide, calcitonin and etidronate was started. The following day the renal function had improved but calcium level was unchanged. Forty-six hours after admission the patient had sudden cardiac arrest and died.¹⁶ Aygenel et al reported a 45-year-old woman with hypercalcemia 24 mg/dL and PTH 5,670 pg/ml. Despite of intravenous hydration, diuretics, bisphosphonate, and calcitonin, calcium level remained unchanged and hemodialysis was started. She died of cardiac arrhythmia before surgical resection of parathyroid adenoma was possible.⁹ Kuan and Tan reported a fatal case of 60-year-old female with primary hyperparathyroidism PTH 1,769 pg/ml and calcium 16.6 mg/dL, despite of rigorous intravenous hydration, pamidronate, calcitonin and hydrocortisone.¹⁷ Pallauf et al reported a 40-year-old male who presented with acute hypercalcemia 26.5 mg/dL, PTH 4,880 pg/ml and creatinine 3.8 mg/dL. With rigorous hydration, calcitonin, denosumab and hemodialysis, calcium level "decreased but could not be normalized". He died of multi-organ failure on day 4.¹³

Hedbäck & Odén conducted a death risk factor analysis of 845 patients who underwent surgery for primary hyperparathyroidism from 1953-1982 and concluded that the amount of diseased parathyroid tissue is a risk factor for death and well-preserved renal function seems to have a protective role.¹⁸ Recently Yu et al analyzed 2,097 patients with untreated primary hyperparathyroidism from 1997 to 2006 and demonstrated that PTH was the only statistically significant risk factor in all-cause mortality, fatal and nonfatal cardiovascular disease. Serum creatinine, alkaline phosphatase and calcium levels were associated with increased risk of short-term mortality.¹⁹

The response of hyperparathyroid crisis to medical management is often unpredictable and transient, surgery remains the

mainstay treatment for primary hyperparathyroidism.^{10,11,16,20} Van den et al reported a 50-year-old man with nausea, vomiting, weight loss, lethargy, serum calcium level 23.6 mg/dL and PTH >1,900 pg/ml, who was successfully managed with parathyroidectomy of a 3.4 x 3.2 x 6.3 cm parathyroid adenoma.¹¹ Wong et al reported a 20-year-old college student presented with left knee pain and multiple lytic bony lesions, calcium level 16 mg/dL and intact PTH 116.9 pmol/ml. The PTH level became normal only after surgery.⁷ Occhetta et al reported a patient with an automatic cardiac defibrillator and refractory ventricular arrhythmia secondary to primary hyperparathyroidism. The ventricular arrhythmia was refractory to medical therapy and only responded to surgical resection of the parathyroid adenoma.⁸ Yu et al recently reported eleven patients with hyperparathyroid crisis receiving more than 72 hours of medical treatment. Three patients were resistant to medical treatment and calcium level remained over 14 mg/dL, six patients had abnormal calcium level <14mg/dL, and only two patients had calcium levels normalize preoperatively, underscoring the importance of early parathyroidectomy.¹²

Conclusion

While hyperparathyroidism usually presented as asymptomatic hypercalcemia, hyperparathyroid crisis still rarely occurs sporadically. In such cases, prompt surgery is recommended after initial medical treatment to maintain hydration, optimize renal function and hypercalcemia.

Figures

Figure 1: Chest radiographs. A. On admission; B. The day after admission; C. Before intubation; D. Twenty-four hours after intubation.

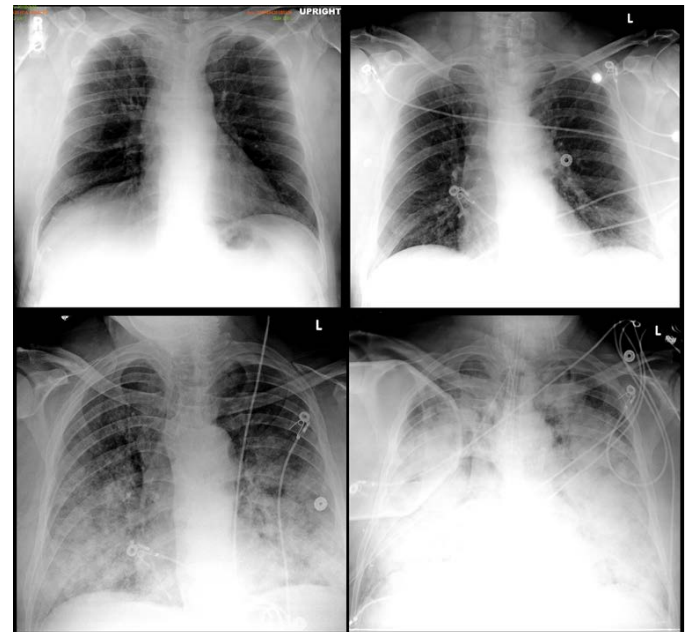
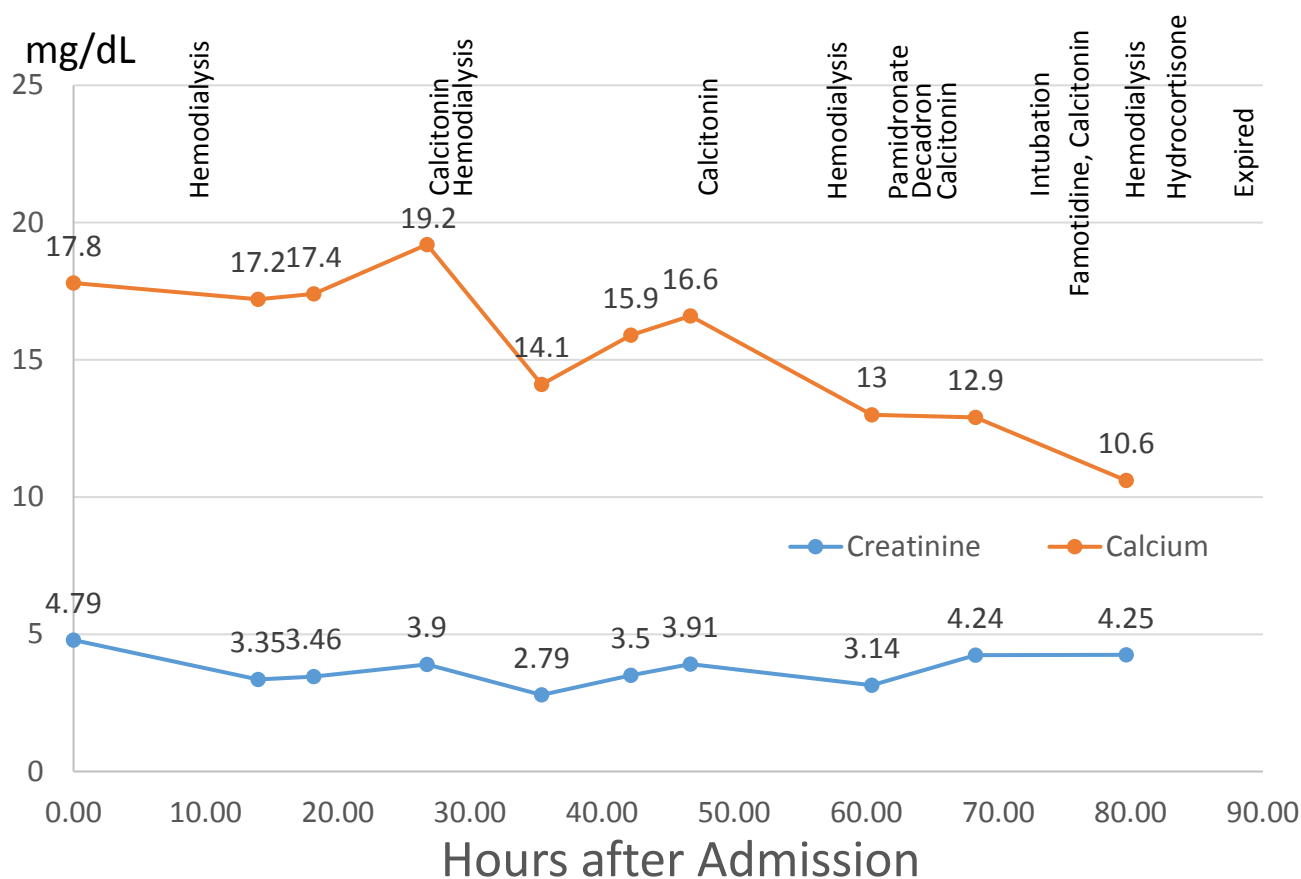


Figure 2: Timeline of clinical course



REFERENCES

1. **Hewson JS.** Parathyroid crisis; a cause of sudden death. *AMA Arch Intern Med.* 1958 Aug;102(2):199-203. PubMed PMID: 13558761.
2. **Schenker JG, Kallner B.** Fatal postpartum hyperparathyroid crisis due to primary chief cell hyperplasia of parathyroids. Report of a case. *Obstet Gynecol.* 1965 May;25:705-9. PubMed PMID: 14289533.
3. **Kelly TR, Zarconi J.** Primary hyperparathyroidism: hyperparathyroid crisis. *Am J Surg.* 1981 Nov;142(5):539-42. PubMed PMID: 7304806.
4. **Keeling CA, Abrahamson MJ, Harloe DG.** Fatal hyperparathyroid crisis. *Postgrad Med J.* 1987 Feb;63(736):111-2. PubMed PMID: 3671236; PubMed Central PMCID:PMC2428225.
5. **Katz JH, Dias SM, Ferguson RP.** Fatal cardiac calcifications secondary to primary hyperparathyroidism. *Am J Med.* 1988 Jul;85(1):122-3. PubMed PMID:3389374.
6. **Gentric A, Pennec YL.** Fatal primary hyperparathyroidism with myopathy involving respiratory muscles in an old woman. *J Am Geriatr Soc.* 1994 Dec;42(12):1306. PubMed PMID: 7983302.
7. **Wong P, Carmeci C, Jeffrey RB, Weigel RJ.** Parathyroid crisis in a 20 year old--an unusual cause of hypercalcaemic crisis. *Postgrad Med J.* 2001 Jul;77(909):468-70. PubMed PMID: 11423601; PubMed Central PMCID: PMC1760986.
8. **Occhetta E, Bortnik M, Magnani A, Francalacci G, Vassanelli C.** Primary hyperparathyroidism and arrhythmic storm in a patient with an implantable cardioverter defibrillator for primary prevention of sudden death. *Europace.* 2004 May;6(3):184-8. PubMed PMID: 15121067.
9. **Aygençel G, Keles A, Demircan A.** Death due to primary hyperparathyroidism. *Saudi Med J.* 2007 Jun;28(6):971. PubMed PMID: 17530124.
10. **Harjit K, Zanariah H, Hisham AN.** Hypercalcaemic crisis: immediate parathyroidectomy and intraoperative intravenous calcium infusion improves outcome. *Asian J Surg.* 2007 Jul;30(3):173-7. PubMed PMID: 17638635.
11. **Van den Hauwe K, Oeyen SG, Schrijvers BF, Decruyenaere JM, Buylaert WA.** A 50-year-old man with severe hypercalcemia: a case report. *Acta Clin Belg.* 2009 Sep-Oct;64(5):442-6. PubMed PMID: 19999395.

12. **Yu HH, Lou SY, Chou YH, Chan HM, Chen HT, Huang SM.** Hyperparathyroid crisis: the timing of surgery. *Asian J Surg.* 2011 Oct;34(4):147-52. doi: 10.1016/j.asjsur.2011.11.004. Epub 2012 Feb 24. PubMed PMID: 22464829.
13. **Pallauf A, Schopohl J, Makeschin M, Kirchner T, Reincke M.** Lethal generalized calcinosis and hypercalcemic crisis in primary hyperparathyroidism. *J Clin Endocrinol Metab.* 2015 Jan;100(1):17-8. doi: 10.1210/jc.2014-2813. PubMed PMID:25343236.
14. **Demers C, Rouleau JL, Leung TK, Tardif JC.** Hypercalcemic cardiomyopathy associated with primary hyperparathyroidism mimicking primary obstructive hypertrophic cardiomyopathy. *Can J Cardiol.* 1998 Nov; 14(11):1397-400. Review. PubMed PMID: 9854522.
15. **Love GL, Samuels M.** Fatal acute hyperparathyroidism and parathyroid carcinoma. *South Med J.* 1983 Mar;76(3): 407-8. PubMed PMID: 6828913.
16. **Polo V, Coen D.** Primary hyperparathyroidism as a surgical emergency. *Am J Emerg Med.* 1995 Nov;13(6): 680-1. PubMed PMID: 7575814.
17. **Kuan YC, Tan F.** Hypercalcemic crisis - a fatal case of primary hyperparathyroidism. *Med J Malaysia.* 2014 Dec;69(6):231-3. PubMed PMID: 25934952.
18. **Hedbäck G, Odén A.** Death risk factor analysis in primary hyperparathyroidism. *Eur J Clin Invest.* 1998 Dec;28(12): 1011-8. PubMed PMID: 9893013.
19. **Yu N, Leese GP, Donnan PT.** What predicts adverse outcomes in untreated primary hyperparathyroidism? The Parathyroid Epidemiology and Audit Research Study (PEARS). *Clin Endocrinol (Oxf).* 2013 Jul;79(1):27-34. doi:10.1111/cen.12206. Epub 2013 Apr 19. PubMed PMID: 23506565.
20. **Schweitzer VG, Thompson NW, Harness JK, Nishiyama RH.** Management of severe hypercalcemia caused by primary hyperparathyroidism. *Arch Surg.* 1978 Apr;113(4):373-81. PubMed PMID: 637707.