

## CLINICAL VIGNETTE

# Acute Hemorrhagic Gastritis during Treatment with PD-1 Inhibitor Nivolumab for Stage IV Endometrial Cancer

Michelle Chong, MD, MPH and Simi Singh, MD

### Background

Programmed cell death protein 1 (PD-1) inhibitors block immune checkpoints and activate the immune system against cancer. They are beneficial for treating many advanced cancers from melanoma to Hodgkin lymphoma.<sup>1</sup> They have also been associated with immune mediated adverse effects, including inflammatory disease of the gastrointestinal tract, most commonly colitis.<sup>1</sup> We present a rare side effect of hemorrhagic gastritis in a patient taking nivolumab for stage IV endometrial cancer.

### Case Report

A 53-year-old woman with Lynch syndrome presented to gastroenterology with 2 weeks of epigastric abdominal pain associated with nausea and vomiting. She had been treated with nivolumab for stage IV endometrial cancer for the preceding three years, with scans showing no evidence of disease after two years of treatment. She was referred by her primary care provider, who had prescribed pantoprazole and ondansetron and obtained normal abdominal ultrasound.

Exam in gastroenterology was unremarkable and sucralfate was prescribed, and upper endoscopy scheduled. Endoscopy showed diffusely and severely erythematous and inflamed stomach mucosa that easily bled with manipulation of the scope (Figure 1).

Stomach biopsies revealed diffusely eroded gastric mucosa with marked acute and chronic inflammation, crypt abscesses, and increased intraepithelial lymphocytes with crypt degeneration and dropout (Figure 2).

Esophageal biopsies showed mildly reactive squamous mucosa with scattered intraepithelial lymphocytes and rare eosinophils. Stains for fungal organisms, CMV, HSV, EBV, and *H. pylori* were negative.

Nivolumab-induced acute hemorrhagic gastritis was suspected, and Nivolumab was held and she was treated with two weeks of prednisone 1mg/kg daily. Her symptoms did not improve after two weeks of prednisone. The dose was increased to 2mg/kg and within one week her symptoms significantly improved. She was slowly tapered off prednisone and remained without recurrent symptoms at 3- month follow-up. She continues off nivolumab with no plans to resume treatment.

### Discussion

Immune checkpoint inhibitors are novel anti-cancer agents with widespread applications. They are notably associated with immune-mediated adverse effects. Within the GI tract, diarrhea is a common symptom reported in about 13% of patients taking PD-1 inhibitors.<sup>1</sup> Other complications include hemorrhagic gastritis. One series of 20 patients with GI immune related adverse effects (irAE) linked to PD-1 inhibitors, reported 20% presenting with upper GI involvement, 40% with acute colitis, 35% with microscopic colitis, and 5% with pseudo-obstruction. Symptoms developed an average of 4.2 months after initiation of therapy.<sup>2</sup>

The diagnosis of PD-1 inhibitor associated gastritis is established with pathologic and endoscopic features in the appropriate clinical context. Common histopathologic findings include lamina propria expansion, intra-epithelial neutrophils, and increased crypt/gland apoptosis.<sup>3</sup> Treatment for PD-1 inhibitor GI irAE varies but includes corticosteroids and discontinuation of therapy, with infliximab considered for refractory disease.<sup>1</sup>

The case was of interest for the significant response of the patient's cancer to PD-1 inhibition, as well as the delayed onset of irAE. Further research is needed to characterize the risk factors for irAE and most appropriate treatment. As immune checkpoint inhibitors become more common, it is important to consider immune-related adverse effects in a patient taking these medications presenting with new-onset of symptoms that may be compatible with these adverse effects.

### Figures

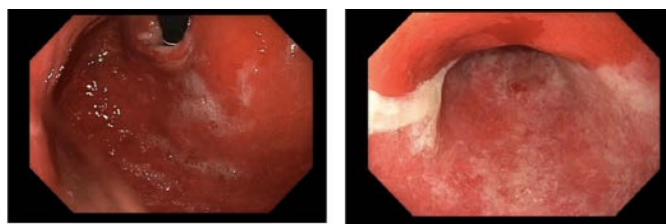


Figure 1.

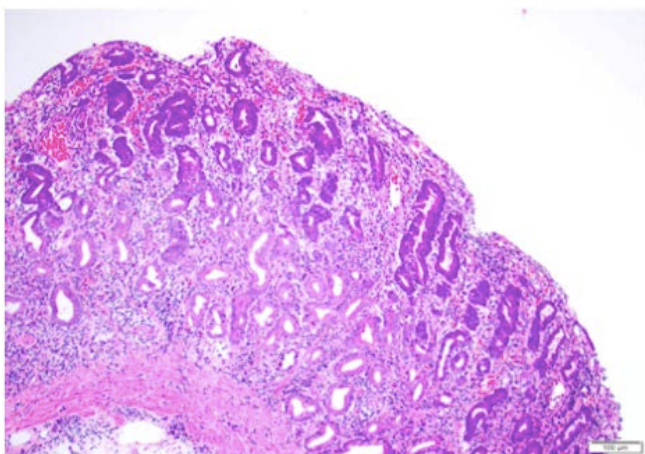


Figure 2.

## REFERENCES

1. **Soularue E, Lepage P, Colombel JF, Coutzac C, Faleck D, Marthey L, Collins M, Chaput N, Robert C, Carbonnel F.** Enterocolitis due to immune checkpoint inhibitors: a systematic review. *Gut*. 2018 Nov;67(11):2056-2067. doi: 10.1136/gutjnl-2018-316948. Epub 2018 Aug 21. Review. PubMed PMID: 30131322.
2. **Gonzalez RS, Salaria SN, Bohannon CD, Huber AR, Feely MM, Shi C.** PD-1 inhibitor gastroenterocolitis: case series and appraisal of 'immunomodulatory gastroenterocolitis'. *Histopathology*. 2017 Mar;70(4):558-567. doi: 10.1111/his.13118. Epub 2016 Dec 20. PubMed PMID: 28000302.
3. **Collins M, Michot JM, Danlos FX, Mussini C, Soularue E, Mateus C, Loirat D, Buisson A, Rosa I, Lambotte O, Laghouati S, Chaput N, Coutzac C, Voisin AL, Soria JC, Marabelle A, Champiat S, Robert C, Carbonnel F.** Inflammatory gastrointestinal diseases associated with PD-1 blockade antibodies. *Ann Oncol*. 2017 Nov 1;28(11):2860-2865. doi: 10.1093/annonc/mdx403. PubMed PMID: 29045560.