

CLINICAL VIGNETTE

Recurrent Spontaneous Coronary Artery Dissection

Ramona Mehrinfar-Zadeh, MD and Ramtin Anousheh, MD

Case

This is a case of a 53 y.o. year old female presented with a non-STEMI to an outside hospital in 2015 and underwent PCI of the left circumflex artery. She was later diagnosed with mitral valve prolapse and severe mitral regurgitation and underwent robotic mitral valve repair and left trial closure in 2016. Her post-operative course was complicated by atrial fibrillation requiring direct current cardioversion and pericardial effusion with pericarditis.

In November 2019 an echocardiogram showed a mildly reduced ejection fraction at 45% and a stress echocardiogram at that time was negative for ischemia. She was on a low dose of beta-blockers, Metoprolol 12.mg Bid, and was recommended to increase her medical therapy for improved control of hypertension, however, she declined.

In April of 2020 she presented to another hospital with chest pain symptoms similar to that she had in 2015 and found have an non-STEMI with a peak troponin of 0.92, without ECG changes. She underwent coronary angiography which revealed spontaneous coronary artery dissection of the distal left anterior descending artery. She was treated with heparin and dual antiplatelet therapy, and her Metoprolol dose was increased to 50mg. Her troponin down trended and her blood pressure control improved. She underwent renal ultrasound to evaluate for fibromuscular dysplasia and it was normal. She was discharged home on dual antiplatelet therapy and Metoprolol.

Six weeks later she had a follow up CT coronary angiogram which showed epicardial fat stranding at the distal LAD corresponding to the area of dissection without progression. Her symptoms had largely resolved and she was able to go on regular walks without exertional symptoms. The images from her prior coronary angiography in 2015 were obtained and reviewed and they were concerning for SCAD as well.

Discussion

Heart disease is a leading cause of death in men and women. As compared with men, women have differing presentations, optimal treatment strategies and outcomes. Spontaneous coronary artery dissection (SCAD) is increasingly recognized as an etiology of myocardial infarction among women, causing about 35% of acute coronary syndromes and is the most common cause of acute MI in pregnancy.¹

SCAD is defined as a non-traumatic, non-iatrogenic separation of the coronary arterial wall and can result in myocardial infarction. It is more common among younger patients, particularly women. The underlying mechanism of non-atherosclerotic SCAD is not fully understood, however two mechanisms have been proposed: intramural hematoma from intimal tear and spontaneous hemorrhage from the vaso vasorum.² As the hematoma expands it can encroach on the true lumen and cause myocardial ischemia and infarction, and it can result in extensive dissection lengths.

Because of the low prevalence of typical cardiovascular risk factors for SCAD, its cause has been thought to be due to underlying arteriopathies, genetic factors, hormonal influences such as pregnancy or systemic inflammatory diseases. Fibromuscular dysplasia (FMD) has been found to be the most commonly reported with this diagnosis.² FMD is non-atherosclerotic, noninflammatory vascular disease that can affect different arterial beds and manifest as stenosis, aneurysm, tortuosity or dissection. Case reports of patients with SCAD and FMD have led some investigators to believe that SCAD is the manifestation of coronary FMD.³

The most commonly affected vessel is the left anterior descending (LAD) artery, although any of the coronary arteries can be affected.¹ Various imaging modalities have been used to diagnose SCAD, however coronary angiography is considered first line. The limitation with angiography is that it visualizes the lumen and not the wall of the vessel, however intracoronary imaging with IVUS and OCT can be used to overcome this limitation.⁴

Additionally, cardiac CT and MRI have also been used, however, these imaging modalities should not be the first choice as cardiac CT can miss a substantial proportion of acute SCAD.

The angiographic appearance of SCAD has been classified into three different types² (figures 1A-1C). Type 1 involves the classic appearance of multiple radiolucent or arterial wall contrast staining. Type 2 involves the presence of diffuse, smooth stenosis that can be of varying severity and length. Type 3 refers to focal or tubular stenosis that is similar to that found in traditional atherosclerotic lesions.

One of the challenges in diagnosing SCAD is that while patients may present with typical ischemic symptoms, their initial ECG

and cardiac biomarkers may be normal. Thus serial evaluations are necessary in patients with suspected presentation of SCAD.

Short and long-term prognosis are important to consider. Short term, patients can experience chest pain, depression, anxiety, recurrent MI, recurrent SCAD, heart failure, stroke and death in up to 30% of cases.² Long-term incidence of major adverse cardiac events has been reported to be as high as 37% at 5-7 years and related to recurrent SCAD.⁵

Recurrent SCAD is an important complication in these patients. SCAD recurrence has been reported to occur in 11-29% of patients at 10 years.² It has been described as either expansion of the intramural hematoma resulting from the index dissection that has not yet healed, or from de novo dissection unrelated to the index event. Coronary tortuosity has been commonly noted in the literature as a risk factor for recurrence, with recurrence most likely to occur in the tortuous segment.^{6,7}

In another study, Saw et al prospectively followed patients with SCAD to determine other potential risk factors and identified that hypertension was an independent risk factor that increased the risk of recurrence.⁸ Interestingly, they also noted that the use of beta-blockers decreased the rate of recurrence by almost two-thirds (HR=0.36, P=0.004). They theorized that since blood pressure control, especially double product control and reducing wall stress, was important in reducing the risk of recurrent aortic dissection, that the same would apply for SCAD. As a result, they recommend beta-blockers as the first-line agent for hypertension in these patients.

The short- and long-term management of SCAD patients is difficult to standardize as there are no randomized controlled trials. What is known is that a conservative approach (non-revascularization), blood pressure control and the use of beta-blockers helps improve the outcomes of these patients.

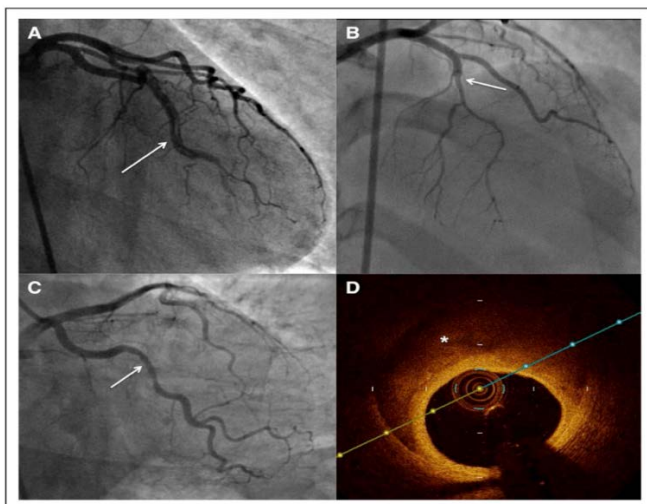


Figure 1. Angiographic appearance of SCAD. A. Type 1. B. Type 2. C. Type 3. D. Optical coherence tomography in type 3 SCAD with the asterisk indicating location of intramural hematoma. Adopted from Hayes et al.²

REFERENCES

1. **Tweet MS, Gulati R, Hayes SN.** What Clinicians Should Know About Spontaneous Coronary Artery Dissection. *Mayo Clin Proc.* 2015 Aug;90(8):1125-30. doi: 10.1016/j.mayocp.2015.05.010. PMID: 26250728.
2. **Hayes SN, Kim ESH, Saw J, Adlam D, Arslanian-Engoren C, Economy KE, Ganesh SK, Gulati R, Lindsay ME, Mieres JH, Naderi S, Shah S, Thaler DE, Tweet MS, Wood MJ; American Heart Association Council on Peripheral Vascular Disease; Council on Clinical Cardiology; Council on Cardiovascular and Stroke Nursing; Council on Genomic and Precision Medicine; and Stroke Council.** Spontaneous Coronary Artery Dissection: Current State of the Science: A Scientific Statement From the American Heart Association. *Circulation.* 2018 May 8;137(19):e523-e557. doi: 10.1161/CIR.0000000000000564. Epub 2018 Feb 22. PMID: 29472380; PMCID: PMC5957087.
3. **Michelis KC, Olin JW, Kadian-Dodov D, d'Escamard V, Kovacic JC.** Coronary artery manifestations of fibromuscular dysplasia. *J Am Coll Cardiol.* 2014 Sep 9;64(10):1033-46. doi: 10.1016/j.jacc.2014.07.014. PMID: 25190240; PMCID: PMC4370367.
4. **Tweet MS, Kok SN, Hayes SN.** Spontaneous coronary artery dissection in women: What is known and what is yet to be understood. *Clin Cardiol.* 2018 Feb;41(2):203-210. doi: 10.1002/clc.22909. Epub 2018 Mar 1. PMID: 29493808; PMCID: PMC5953427.
5. **Lettieri C, Zavalloni D, Rossini R, Morici N, Etti F, Leonzi O, Latib A, Ferlini M, Trabattini D, Colombo P, Galli M, Tarantini G, Napodano M, Piccaluga E, Passamonti E, Sganzerla P, Ielasi A, Coccato M, Martinoni A, Musumeci G, Zanini R, Castiglioni B.** Management and Long-Term Prognosis of Spontaneous Coronary Artery Dissection. *Am J Cardiol.* 2015 Jul 1;116(1):66-73. doi: 10.1016/j.amjcard.2015.03.039. Epub 2015 Apr 8. PMID: 25937347.
6. **Eleid MF, Guddeti RR, Tweet MS, Lerman A, Singh M, Best PJ, Vrtiska TJ, Prasad M, Rihal CS, Hayes SN, Gulati R.** Coronary artery tortuosity in spontaneous coronary artery dissection: angiographic characteristics and clinical implications. *Circ Cardiovasc Interv.* 2014 Oct;7(5):656-62. doi: 10.1161/CIRCINTERVENTIONS.114.001676. Epub 2014 Aug 19. PMID: 25138034.
7. **Main A, Prakash R, Starovoytov A, Sabbaghan A, Aymong E, Mancini GBJ, Saw J.** Characteristics of extension and de novo recurrent spontaneous coronary artery dissection. *EuroIntervention.* 2017 Dec 8;13(12):e1454-e1459. doi: 10.4244/EIJ-D-17-00264. PMID: 28891472.
8. **Saw J, Humphries K, Aymong E, Sedlak T, Prakash R, Starovoytov A, Mancini GBJ.** Spontaneous Coronary Artery Dissection: Clinical Outcomes and Risk of Recurrence. *J Am Coll Cardiol.* 2017 Aug 29;70(9):1148-1158. doi: 10.1016/j.jacc.2017.06.053. PMID: 28838364.