

CLINICAL VIGNETTE

Gastrointestinal Manifestations of Henoch-Schönlein Purpura

Vikas Pabby, MD

A 54-year-old male presented with abdominal pain, rectal bleeding, and skin ulcerations. His rash developed on the legs and buttocks, then spread to the back, abdomen, and chest (Figures 1-3). The ankles were affected the most, and there was sparing of the palms and soles. He had palpable purpura which resolved, but subsequently new flat red lesions. The onset of the abdominal pain was 1-2 weeks after the rash. The abdominal pain persisted for 2 weeks with one episode of bloody stool.

On examination he had erythematous vascular macules and patches in the upper extremities, trunk, and lower extremities. The CRP was 4.0 and the creatinine was 0.74.

He underwent CT angiogram of the abdomen and pelvis which showed patent abdominal vasculature, with thickened enhancing walls of few ileal loops in the pelvis with adjacent fluid collection extending to perirectal region.

Esophagoduodenoscopy (EGD) showed normal esophagus and gastric mucosa. In the duodenum, there was nodular mucosa. The nodules were erythematous with superficial erosions (Figure 4). Colonoscopy showed superficial erosions and nodules in the distal 15 cm of the ileum. There was mildly erythematous mucosa in the entire colon and congested mucosa in the cecum (Figure 5). Pathology showed patchy surface erosions and moderate acute inflammation in the duodenum, minimal lamina propria acute inflammation in the terminal ileum, and patchy mild surface reactive changes and minimal lamina propria acute inflammation, non-specific, in the colonic mucosa. These findings were determined to be secondary to mild ischemic injury due to vasculitis.

The patient underwent punch biopsy of the right wrist skin which showed 1+ deposition of IgA (granular), IgG (fibrillar), and fibrinogen (fibrillar) in upper dermal vessels consistent with an IgA vasculitis, including Henoch-Schönlein purpura.

The patient was treated with a Prednisone taper with improvement in symptoms.

Discussion

Henoch-Schönlein purpura (HSP) is the most common childhood vasculitis, but may also affect adults. It is a type III hypersensitivity mediated small vessel vasculitis characterized by palpable purpura, arthritis, glomerulonephritis and gastrointestinal manifestations. Ninety percent of patients affected are younger than 10 years of age.¹ HSP is a systemic, small-

vessel immunoglobulin A (IgA) dominant vasculitis thought to be secondary to IgA depositions in blood vessel walls in the affected organs, mostly skin, gastrointestinal tract, joints and kidneys.

Gastrointestinal (GI) symptoms including colicky abdominal pain (86%), nausea, vomiting, anorexia, diarrhea, occult blood loss, and less commonly hematochezia.² GI bleeding is more common in adults (59.1%) compared to children (28.3%).³ Intussusception is a common complication of HSP in children but less common in adults. Bowel perforation is rare, but may result from intussusception. GI symptoms are thought to result from submucosal and subserosal hemorrhages and from edema in the bowel wall due to underlying vasculitis.^{4,5}

Aside from GI manifestations of HSP, there may be renal manifestations, dermatological symptoms, arthralgias, and less frequent complications which include pulmonary hemorrhage, myocardial infarction, orchitis. Adults are more likely to have severe kidney disease. Renal involvement in HSP is seen in 40%-50% patients. Most cases have renal manifestations, ranging from asymptomatic hematuria to progressive glomerulonephritis, by the first month, but it may develop months to years after initial presentation. The earliest manifestation in majority of patients (approximately 70%) is skin lesions characterized by purpura and erythematous papules, typically in dependent locations like lower extremities and gluteal regions.⁶

To diagnose HSP, the presence of at least 2 of the following are required which results in identification of the illness with 87.1% sensitivity and 87.7% specificity: palpable purpura, age younger than 20 years at the onset of symptoms, bowel angina, and a biopsy with granulocytes in the vascular wall referred to as leukocytoclastic vasculitis (LCV).⁷ EGD and colonoscopy findings may include erythema/petechiae, erosion/ulceration, edema, atrophy, and hemorrhage.⁸ The second portion of the duodenum is more commonly involved when compared to the duodenal bulb. Imaging findings include multifocal bowel thickening with mucosal hyperenhancement. The bowel thickening involves skip areas of the intestine. Occasionally, there may be a characteristic “target” sign seen on imaging.

Uncomplicated HSP may be self-limiting. Corticosteroids may be effective in patients with GI, renal, and joint, but they are not proven effective for treating organ manifestations and complications, such as glomerulonephritis. Mycophenolate mofetil or cyclosporine A are often used with renal involvement.

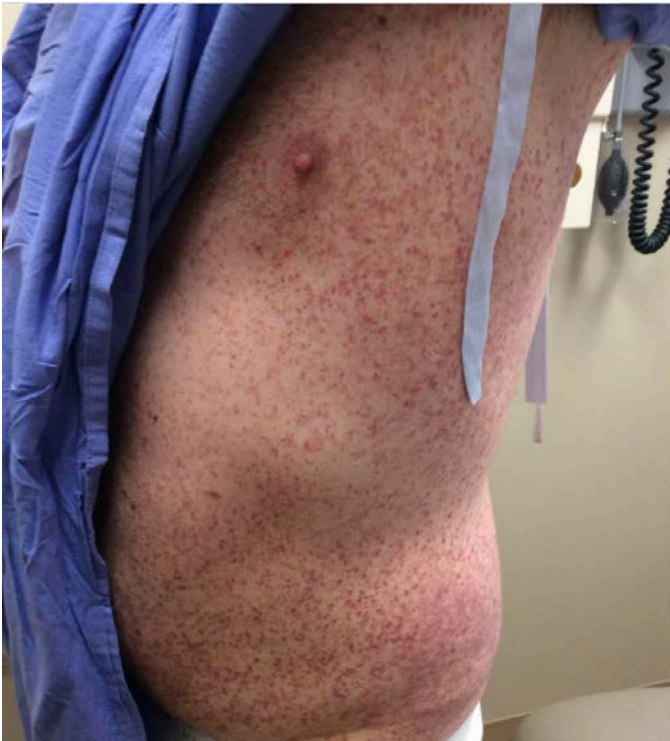

Figure 1: Trunk showing red macular lesions.

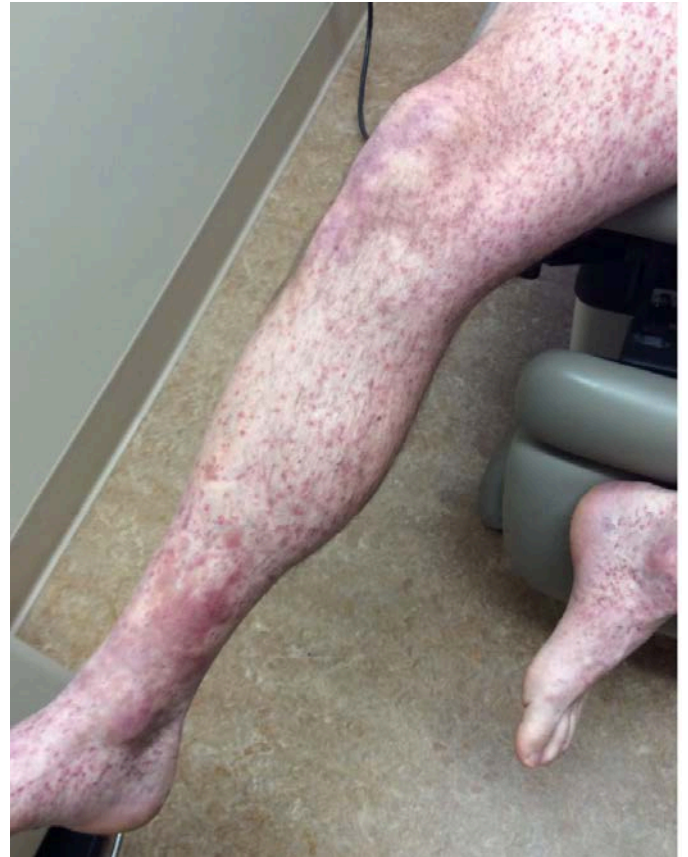

Figure 3: Right lower extremity showing purpura and red macular lesions.

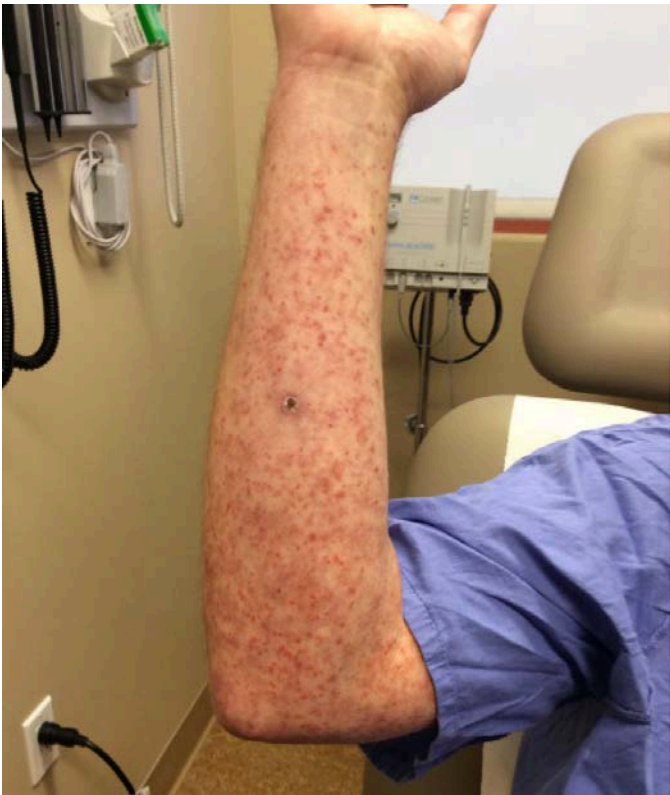

Figure 2: Right upper extremity showing red macular lesions.

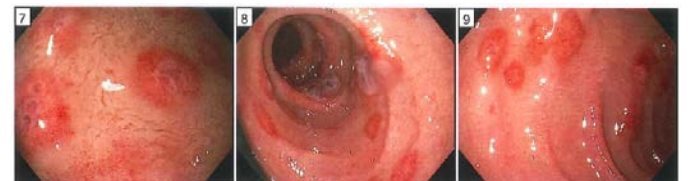

Figure 4: Esophagoduodenoscopy (EGD) showing erythematous nodules and superficial erosions in the duodenum.

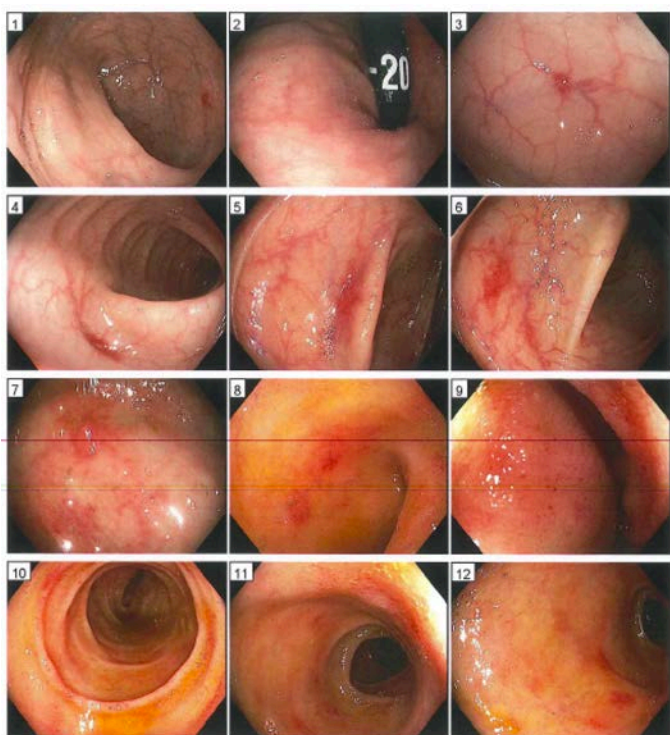


Image 5: Colonoscopy showed mildly erythematous mucosa in the entire colon and congested mucosa in the cecum.

REFERENCES

1. **Hsu HL, Hsiao CH, Liu KL.** Henoch-Schönlein purpura. *Clin Gastroenterol Hepatol.* 2010 Aug;8(8):e83-4. doi: 10.1016/j.cgh.2010.02.011. Epub 2010 Mar 1. PMID: 20197114.
2. **Kaswala D, Chodos A, Ahlawat S.** Henoch-Schonlein Purpura With Gastrointestinal Involvement in an Adult Patient. *Gastroenterol Hepatol (N Y).* 2016 May;12(5):321-3. PMID: 27499714; PMCID: PMC4973562.
3. **Blanco R, Martínez-Taboada VM, Rodríguez-Valverde V, García-Fuentes M, González-Gay MA.** Henoch-Schönlein purpura in adulthood and childhood: two different expressions of the same syndrome. *Arthritis Rheum.* 1997 May;40(5):859-64. doi: 10.1002/art.1780400513. PMID: 9153547.
4. **Novák J, Márki-Zay J, Csiki Z, Sebesi J, Takáts A, Sipka S.** Die Schoenlein-Henoch-Purpura bei erwachsenen. (Gastrointestinale Manifestation und Endoskopie) [Schoenlein-Henoch purpura in adulthood (gastrointestinal manifestation and endoscopy)]. *Z Gastroenterol.* 2001 Sep;39(9):775-82. German. doi: 10.1055/s-2001-17195. PMID: 11558068.
5. **Ashton H, Frenk E, Stevenson CJ.** Therapeutics. XV. The management of Henoch-Schonlein purpura. *Br J Dermatol.* 1971 Aug;85(2):199-203. doi: 10.1111/j.1365-2133.1971.tb07216.x. PMID: 4936860.
6. **Prathiba Rajalakshmi P, Srinivasan K.** Gastrointestinal manifestations of Henoch-Schonlein purpura: A report of two cases. *World J Radiol.* 2015 Mar 28;7(3):66-9. doi: 10.4329/wjr.v7.i3.66. PMID: 25825636; PMCID: PMC4374091.
7. **Mills JA, Michel BA, Bloch DA, Calabrese LH, Hunder GG, Arend WP, Edworthy SM, Fauci AS, Leavitt RY, Lie JT, et al.** The American College of Rheumatology 1990 criteria for the classification of Henoch-Schönlein purpura. *Arthritis Rheum.* 1990 Aug;33(8):1114-21. doi: 10.1002/art.1780330809. PMID: 2202310.
8. **Han Y, Jin SY, Kim DW, Jeon YM, Kim YH, Choi IH.** Endoscopic and microscopic findings of gastrointestinal tract in Henoch-Schönlein purpura: Single institute experience with review of literature. *Medicine (Baltimore).* 2019 May;98(20):e15643. doi: 10.1097/MD.00000000000015643. PMID: 31096484; PMCID: PMC6531244.