

3 A Novel Approach to Emergency Medicine Resident Orientation Using the Flipped Classroom Model

Amick C, Barrie M, Way D, Mitzman J, Greenberger S, , King A/The Ohio State University Wexner Medical Center, Columbus, OH

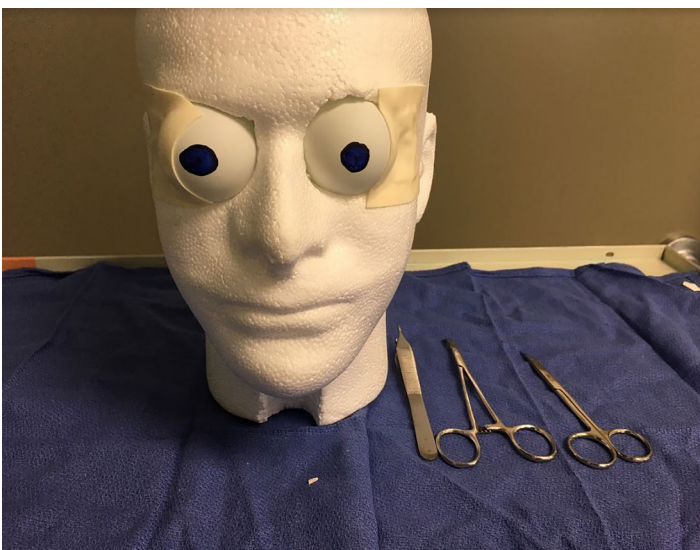
Background: Emergency Medicine (EM) residencies perform an orientation for new interns. There does not seem to be consensus among programs regarding the length, content, or objectives of orientation curricula. Our goal for intern orientation was to offer a sufficient amount of time, guidance, and educational content to provide new interns with baseline knowledge of emergency medicine core content, enable them to work efficiently in our emergency department, and provide learners with the skills to succeed in residency.

Educational Objectives:

1. Bridge knowledge gaps of EM core content and ensure all learners meet our minimum medical knowledge and level one milestone requirements irrespective of their prior educational background
2. Provide administrative strategies, professionalism standards, and efficiency tools to succeed in EM residency and to complete milestones.

Curricular Design: Orientation was performed throughout the month of July 2016. The orientation curriculum included small group core content sessions using the “flipped classroom model,” clinical shifts in our emergency departments, a clinical and citywide scavenger hunt, ultrasound training, airway management, and charting efficiency workshops. Core faculty and third year EM residents created content based on common chief complaints and topics including chest pain, abdominal pain, shortness of breath, airway management, headache, back pain, etc. The content was presented in 55-minute case based interactive small group sessions. These included 2-3 cases where differential diagnosis, management, and disposition were discussed for each case. Prior to each session, interns were given the cases and targeted readings. Interns were also encouraged to use FOAMED resources.

Impact/Effectiveness: We provided core content material in a way that was interactive and improves retention in adult learners. Medical knowledge scores from the annual intern exam administered both before and after the curriculum showed a significant improvement in fund of knowledge (see figure and tables). General survey data indicated that interns felt more comfortable with core content after completing orientation; however, charting lectures did not prepare interns enough for the medical decision making portion of charting, which we intend to improve.



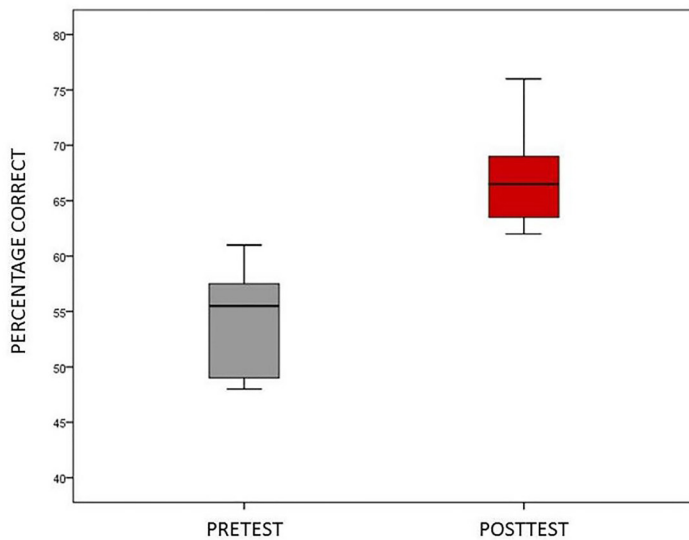


Figure 1. Examination Scores for 12 Interns before (Pre) and after (Post) Orientation Program.

Table 1. Descriptive statistics and paired t-test results for twelve emergency medicine interns on their before (pre) and after (post) orientation examination.

	Mean Scores	Standard Deviation	Mean Difference	t-value	df	p	ES*
Pre-Test	54.33	4.83	-12.58	-6.78	11	.000	-2.73
Post-Test	66.92	4.38					

*ES=Cohen's D effect size

4 A Novel Curriculum for Teaching Emergency Medicine Residents How to Break Bad News

Hall M, Dubosh N, Ullman E/Beth Israel Deaconess Medical Center, Boston, MA

Background: Breaking bad news in the ED is a critical part of Emergency Medicine. Previous research has called for increased teaching of communication skills to EM residents. Recent research has found that few EM providers were trained to deliver bad news during their residency training. There has been previous work describing death notification in the ED and talking with families of critically ill patients in the ICU setting but little has been published describing how to discuss critically ill patient in the ED.

Educational Objectives: To develop a multidisciplinary team approach to teach EM residents how to deliver bad news (both death notification and sudden critical illness) specifically in the ED setting and to study its implementation.

Curricular Design: EM residents participated in a simulation case where a patient became critically ill and

then expired. Twice during this encounter they updated a family member, played by a volunteer actor they had never met, about the case. All cases were videotaped and the interactions was graded by independent reviewers. Residents then participated in a novel curriculum aimed at teaching critical elements of breaking bad news. This session was led by ED attendings and social workers and was comprised of lecture, video presentation, small group roll playing, and discussion. The initial presentation gave an introduction to the topic while the small groups allowed the residents to practice their new skills with real-time feedback. Following the didactic session, residents again participated in a simulation case with hospital volunteer “family members” and their skills discussing the case were again graded. These pre/post evaluations were compared to evaluate the success of the teaching session.

Impact/Effectiveness: Outcome measures are not yet available. Previous projects regarding breaking bad news in the ED have focused on only death notification or used techniques developed in non-ED settings. A recent survey of attendings demonstrated that few received EM specific training in breaking bad news. All EM doctors will unfortunately have to deliver bad news frequently during their careers and increasing training during residency will improve this necessary skill.

5 A Novel Eye Model for Simulation in Slit Lamp Examination, Ultrasound and Foreign Body Removal Using Animal Tissue

Coleman K, Fortuna T, Kuehl D/Virginia tech/Carilion School of Medicine, Roanoke, VA

Background: We sought to develop an inexpensive simulation model that could be used for instruction of the emergency medicine model of practice for ophthalmologic complaints. While synthetic phantoms and models using foodstuffs have been described, animal tissue in a lifelike facsimile has not been fully explored.

Educational Objectives: Gain familiarity and psychomotor skills for competently addressing ocular emergencies to include:

1. Perform Slit lamp examination of both normal anatomy and corneal defects
2. Successfully remove foreign bodies and rust rings
3. Execute an ultrasound examination to include appreciation of normal anatomy, foreign bodies, vitreous hemorrhage and retinal detachment

Curricular Design: Using Styrofoam wig holders and animal tissue, we constructed a model for use with ultrasound and slit lamp examination. For this example, eyes from recently harvested specimens of *Odocoileus virginianus* (Virginia white tailed deer) were used. Each