

ORIGINAL RESEARCH

Diagnosis of Hip Effusion with Bedside Ultrasound in the Emergency Department

Faye Maryann Lee, Medical Student: UCI College of Medicine

J. Christian Fox, MD, RDMS: Assistant Clinical Professor, Director of Emergency Ultrasound; UCI Department of Emergency Medicine

Correspondence:

J. Christian Fox, MD RDMS
Assistant Clinical Professor of Emergency Medicine
Director of Emergency Ultrasound
Department of Emergency Medicine
University of California, Irvine Medical Center
101 City Drive – Route 128
Orange, CA 92868
jfox@uci.edu

INTRODUCTION

The use of bedside ultrasound by emergency physicians has dramatically increased over the past twelve years¹. Its use has led to increased speed of diagnosis, expedited disposition, and improved quality of emergency care²⁻⁴. While there are eight primary applications of emergency ultrasound, its increasing presence in the emergency department (ED) has led to broader utilization of this diagnostic modality. One of the primary applications, ultrasound-guided line placement, requires the use of a linear higher frequency probe. As this probe becomes more widely available to emergency physicians, its utility is expanding into other diagnostic applications. We describe its use in a patient who presented to the ED with left hip pain. The ED attending performed a bedside ultrasound, which demonstrated an effusion in the left hip joint. Orthopedic surgery was consulted; arthrocentesis revealed a white blood cell (WBC) count of 108,000 /uL and the patient was immediately taken to the OR for washout of his hip.

CASE

A 54 year-old male with a history of a septic hip on the right in 1996 and of gout; presented to the ED with left hip pain that was present for one week and spontaneously remitted. It returned again one day prior to his presentation and had remained constant. He denied history of antecedent skin sores, trauma, or injury to his left hip. He reported no risk factors for sexually transmitted diseases (STDs) and denied fevers, chills, nausea or vomiting. His last gouty flare-up was one year prior, though he had never experienced a flare-up in his hips. The patient did report multiple prior joint aspirations for gout, including aspiration of his right ankle. He also reported a history of peptic ulcer disease and lumbar degenerative joint disease.

In 1996 the patient underwent incision and drainage of his right hip. The synovial fluid was reportedly purulent with 118,000 WBCs/uL, 29,000 red blood cells/uL (RBCs) with negative cultures and gram stain. In addition the patient had undergone appendectomy and three gastric ulcer surgeries. On admission the patient was taking -celecoxib and indomethacin. He reported no known drug allergies. The patient was married with a social history significant for discontinued use of alcohol five years prior and smoking two packs per day for the prior 30 years. He denied any drug use. On review of systems, the patient denied any kidney problems, cardiac abnormalities, hypertension, history of myocardial infarction, cerebrovascular accident, peripheral vascular disease or bleeding diathesis. On admission his vital signs were a pulse of 68, a respiratory rate of 20 per minute, blood pressure of 98/66, and a temperature of 36.1 degrees Celsius. On physical exam, the patient was found with his left knee in slight flexion on a pillow. He had decreased range of motion of the left hip (20-90 degrees with moderate pain) with external and internal rotation severely limited secondary to severe pain. Some left groin nodes with tenderness to palpation in the deep groin and deep buttock areas were also noted. There was no palpable back tenderness. All other physical findings were unremarkable.

Laboratory results on admission revealed: WBC of 24,000/uL with 90% neutrophils, hematocrit of 31 g/dL and 302,000 platelets/uL. Radiographic plain films of the hips showed minimal degenerative changes of the hips bilaterally and were otherwise negative.

A bedside ultrasound was performed by the attending emergency physician using an 8 MHz linear probe (BK Ultrasound, Copenhagen, Denmark). The probe was placed along each hip joint in a sagittal plane using an anterior approach (Figure 1). This demonstrated a significant effusion within the patient's left hip joint (Image 1) and no significant findings on the right. Orthopedic surgery was consulted and the joint was aspirated under fluoroscopy revealing 15 cc of turbid and purulent-looking fluid. Analyses of this fluid showed 108,000 WBCs/uL with 95% neutrophils, rare red cells, no crystals or organisms on gram stain and no acid-fast bacilli. Culture of the aspirate was positive only for rare non-viable gram-positive cocci in chains. Cultures were negative for *Neisseria gonorrhoeae*, aerobes, anaerobes, mycobacteria and fungus. Other notable laboratory findings included an erythrocyte sedimentation rate of 28 mm/hr, and C-reactive protein of 4.3 mg/dL. Serum uric acid and complement levels were within normal limits. The patient was started on cefazolin

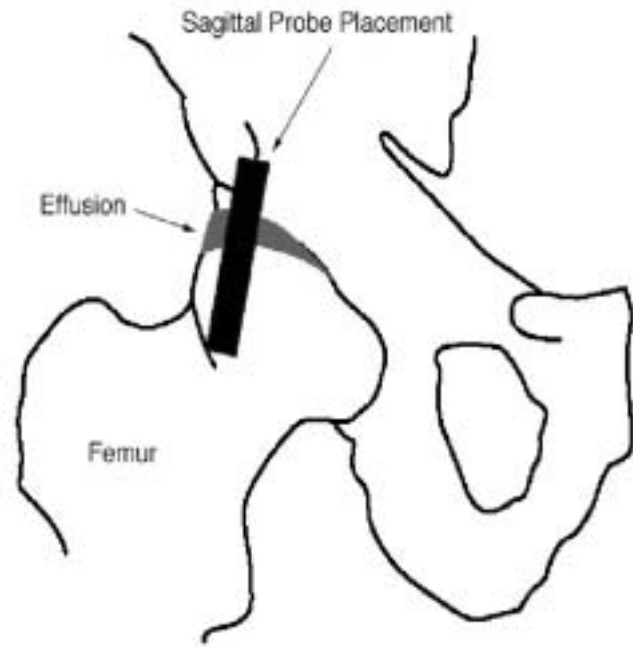


Figure 1: Schematic diagram of sagittal approach

empirically and immediately taken to the operating room. Subsequent incision and debridement of the left hip revealed another 15 cc of blood tinged purulent fluid. The cartilage was intact and appeared to be in good condition. Pathologic study of the excised left hip synovium showed mild acute and chronic inflammation and moderate fibrosis. Cultures of this excised synovium were negative as well. The patient tested negative for tuberculosis and chlamydia.

The patient was given a PICC line and placed on intravenous nafcillin and oral metronidazole, both for three weeks duration. He continued to improve clinically and was discharged on hospital day four with instructions to follow up with orthopedic, infectious disease, and rheumatology physicians.

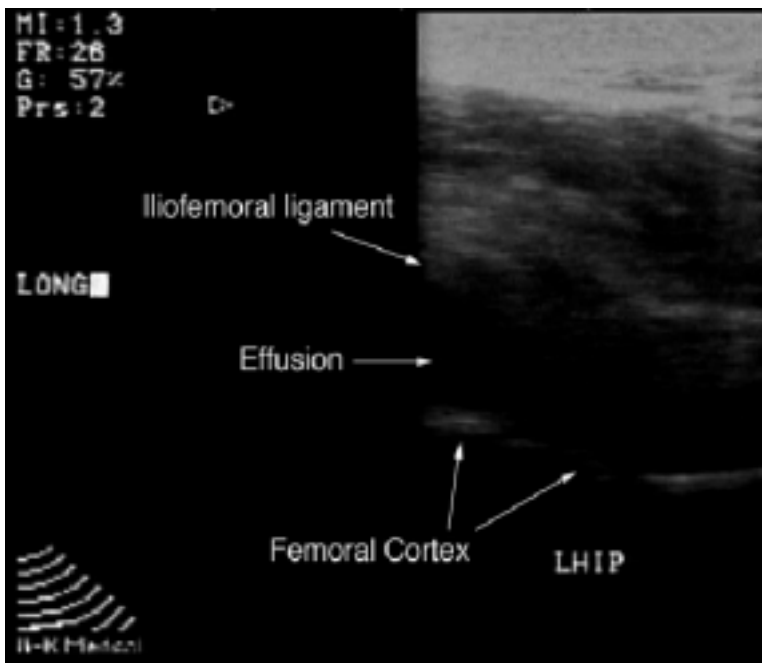


Image 1: Sagittal View of Left Hip

Subsequent work-up of the patient revealed a positive rheumatoid factor.

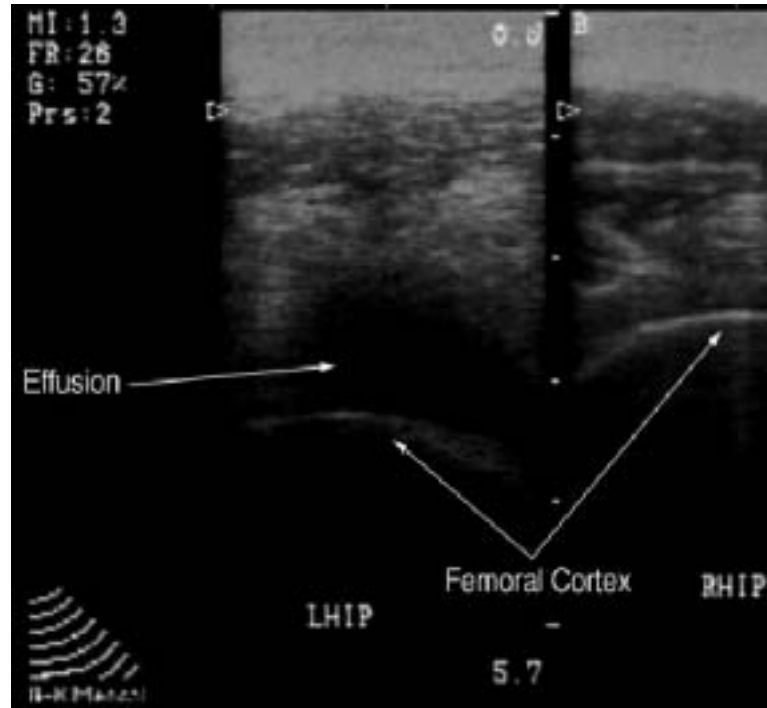
Image 2: Transverse View of Bilateral Hips

DISCUSSION

Monoarticular joint pain is a common presenting complaint in the ED. Often the diagnosis can be gleaned from a thorough history and physical. However, in this patient the signs and symptoms were more subtle, the course benign, and a discharge to home was strongly considered. The availability of the high frequency linear probe and the images obtained of the joint effusion dramatically changed the outcome of this patient's care. Instead of going home with pain medications, the patient went directly to the operating room, completed a four-day hospital course, and was discharged with a course of parenteral antibiotics. The ultrasound not only redirected our decision making process, but aided in convincing orthopedic consultants of the need for an aggressive diagnostic and therapeutic approach.

Linear probes use the higher frequency range of ultrasound (5-8 MHz) and are useful to image structures that lie within five cm of the probe. The applications are many and include: central line placement⁵⁻⁶, visualization of testicular⁷⁻⁹ and ocular¹⁰⁻¹² structures and blood flow, screening for deep venous thrombosis¹³⁻¹⁴, fracture reduction¹⁵⁻¹⁶, localization and identification of abscesses¹⁷⁻¹⁹, and foreign body removal²⁰⁻²⁴. In this case and others, ultrasound has further proven its utility by aiding in the diagnosis of joint effusion²⁵⁻²⁷. Its portability, availability, and ease of use are factors leading to the widening range of applications and increasing use by emergency physicians.

TECHNIQUE IN DETAIL



The anterior recess of the hip is best evaluated in a sagittal approach by placing the probe parallel to the long axis of the femoral neck using a 5-8 MHz linear transducer. The patient should be positioned supine with the hip in slight flexion and internal rotation. Externally rotating the hip will result in the fluid being displaced posteriorly and out of the scanning plane. Deep to the iliopsoas muscle, the hyperechoic structure seen in front of the femoral cortex corresponds to the iliofemoral ligament. In the case of effusion, this hyperechoic ligament is displaced from the femoral neck by the hypoechoic band of fluid. The dramatic difference between bone and fluid decreases the chances of confusing muscle or tendon with effusion. It is useful to scan the contralateral hip for comparison. It may also be helpful to range the joint, identifying moving structures as tendons and muscles.

Ultrasound is sensitive and specific for diagnosing hip effusions²⁸. In both septic arthritis and inflammatory disorders, the effusion is homogeneously hypoechoic. Aspiration can be performed under ultrasound guidance by aligning the effusion in a transverse plane down the center of the ultrasound screen. The needle

is then aimed at the center of the probe and inserted until the reverberation artifact is seen within the fluid collection²⁹.

REFERENCES

- Mateer JR, Jehle D. Ultrasonography in emergency medicine. *Acad Emerg Med.* 1994 Mar-Apr;1(2):149-52.
- Rothschild J. Ultrasound guidance of central vein catheterization; Making health care safer: A critical analysis of patient safety practices. Agency for Healthcare Research and Quality (<http://www.ahrpr.gov/clinic/ptsafety/chap21.htm>).
- Blaivas M, Sierzenski P, Plecque D, et al. Do emergency physicians save time when locating a live intrauterine pregnancy with bedside ultrasonography? *Acad Emerg Med.* 2000;7:988-993.
- Plummer D, Brunetta D, Asinger R, et al. Emergency department echocardiography improves outcome in penetrating cardiac injury. *Ann Emerg Med.* 1992;21(6):709-712.
- Keyes LE, Frazee BW, Snoey ER, Simon BC, Christy D. Ultrasound-guided brachial and basilic vein cannulation in emergency department patients with difficult intravenous access. *Ann Emerg Med.* 1999 Dec;34(6):711-4.
- Miller AH, Roth BA, Mills TJ, Woody JR, Longmoor CE, Foster B. Ultrasound guidance versus the landmark technique for the placement of central venous catheters in the emergency department. *Acad Emerg Med.* 2002 Aug;9(8):800-5.
- Nussbaum Blask AR, Bulas D, Shalaby-Rana E, Rushton G, Shao C, Majd M. Color Doppler sonography and scintigraphy of the testis: a prospective, comparative analysis in children with acute scrotal pain. *Pediatr Emerg Care.* 2002 Apr;18(2):67-71.
- Oyen RH. Scrotal ultrasound. *Eur Radiol.* 2002 Jan;12(1):19-34.
- Wu HC, Sun SS, Kao A, Chuang FJ, Lin CC, Lee CC. Comparison of radionuclide imaging and ultrasonography in the differentiation of acute testicular torsion and inflammatory testicular disease. *Clin Nucl Med.* 2002 Jul;27(7):490-3. PMID: 12072775 [PubMed - indexed for MEDLINE]
- Blaivas M. Bedside emergency department ultrasonography in the evaluation of ocular pathology. *Acad Emerg Med.* 2000 Aug;7(8):947-50.
- Blaivas M, Theodoro D, Sierzenski PR. A study of bedside ocular ultrasonography in the emergency department. *Acad Emerg Med.* 2002 Aug;9(8):791-9.
- Klein OG Jr. The initial evaluation in ophthalmic injury. *Otolaryngol Clin North Am.* 1979 May;12(2):303-20.
- Jacobson AF. Diagnosis of deep venous thrombosis. A review of radiologic, radionuclide, and non-imaging methods. *Q J Nucl Med.* 2001 Dec;45(4):324-33.
- Michiels JJ, Kasbergen H, Oudegraaf R, Van Der Graaf F, De Maeseneer M, Van Der Planken M, Schroyens W. Exclusion and diagnosis of deep vein thrombosis in outpatients by sequential noninvasive tools. *Int Angiol.* 2002 Mar;21(1):9-19.
- Chern TC, Jou IM, Lai KA, Yang CY, Yeh SH, Cheng SC. Sonography for monitoring closed reduction of displaced extra-articular distal radial fractures. *J Bone Joint Surg Am.* 2002 Feb;84-A(2):194-203.
- Durstun W, Swartzentruber R. Ultrasound guided reduction of pediatric forearm fractures in the ED. *Am J Emerg Med.* 2000 Jan;18(1):72-7.
- Blaivas M. Ultrasound-guided breast abscess aspiration in a difficult case. *Acad Emerg Med.* 2001 Apr;8(4):398-401.
- Chern CH, Hu SC, Kao WF, Tsai J, Yen D, Lee CH. Psoas abscess: making an early diagnosis in the ED. *Am J Emerg Med.* 1997 Jan;15(1):83-8.
- Hoffner RJ, Kilagblian T, Esekogwu VI, Henderson SO. Common presentations of amebic liver abscess. *Ann Emerg Med.* 1999 Sep;34(3):351-5.
- Graham DD Jr. Ultrasound in the emergency department: detection of wooden foreign bodies in the soft tissues. *J Emerg Med.* 2002 Jan;22(1):75-9.
- Hill R, Conron R, Greissinger P, Heller M. Ultrasound for the detection of foreign bodies in human tissue. *Ann Emerg Med.* 1997 Mar;29(3):353-6.
- Schlager D. Ultrasound detection of foreign bodies and procedure guidance. *Emerg Med Clin North Am.* 1997 Nov;15(4):895-912.
- Schlager D, Sanders AB, Wiggins D, Boren W. Ultrasound for the detection of foreign bodies. *Ann Emerg Med.* 1991 Feb;20(2):189-91.
- Yanay O, Vaughan DJ, Diab M, Brownstein D, Brogan TV. Retained wooden foreign body in a child's thigh complicated by severe necrotizing fasciitis: a case report and discussion of imaging modalities for early diagnosis. *Pediatr Emerg Care.* 2001 Oct;17(5):354-5.
- Bierma-Zeinstra SM, Bohnen AM, Verhaar JA, Prins A, Ginai-Karamat AZ, Lameris JS. Sonography for hip joint effusion in adults with hip pain. *Ann Rheum Dis.* 2000 Mar;59(3):178-82.
- Valley VT, Stahmer SA. Targeted musculoarticular sonography in the detection of joint effusions. *Acad Emerg Med.* 2001 Apr;8(4):361-7.
- Wang SC, Chhem RK, Cardinal E, Cho KH. Joint sonography. *Radiol Clin North Am.* 1999 Jul;37(4):653-68.
- Wilson DJ, Green DJ, MacLarnon JC. Arthrosonography of the painful hip. *Clin Radiol.* 1984 Jan;35(1):17-9.
- Smith SW. Emergency physician-performed ultrasonography-guided hip arthrocentesis. *Acad Emerg Med.* 1999;6: 84-6.