

ORIGINAL RESEARCH

A Modified Approach to Supraclavicular Subclavian Vein Catheter Placement: The Pocket Approach

Julie Gorchynski, MD¹
Worth W. Everett, MD²
Eleni Pentheroudakis, MD¹

¹ Department of Emergency Medicine, University of California Irvine, Orange, California, USA

² Department of Emergency Medicine, University of Pennsylvania, Philadelphia, Pennsylvania, USA

ABSTRACT

BACKGROUND: Central venous access is often necessary for the administration of fluids, blood products, and medications. Several approaches to supraclavicular subclavian venous access have been described. This study examines the effectiveness of central venous catheter placement utilizing an alternative set of anatomic landmarks for supraclavicular subclavian vein access. **METHODS:** This was a two phase study. The first portion involved subclavian vein cannulation using a supraclavicular approach in 28 cadavers. The specific set of anatomic landmarks for the supraclavicular approach, termed the “pocket approach,” is described. Cadavers were subsequently dissected to verify appropriate line placement. The second portion was a chart review of Emergency Department (ED) patients who underwent attempted subclavian vein catheter placement utilizing the pocket approach. Charts were extracted following education of the ED faculty and resident staff to determine: 1) Success of subclavian line placement, 2) The incidence of pneumothorax, and 3) The use of supraclavicular subclavian access in the trauma setting, during cardiopulmonary resuscitation (CPR), and in patients who had cervical collars. **RESULTS:** In 28 cadavers, the success rate of the pocket approach was 100% (34/34; 95% CI 90% to

100%). Chart review of the 68 patients revealed a success rate of 90% (61/68; CI 80% to 96%). No pneumothoraces were recorded (0/68; CI 0% to 5%). The pocket approach was used successfully in 11 patients with cervical collars, (100%, CI 72% to 100%) and in 15 of 16 patients undergoing CPR (94%, CI 70% to 100%). In four fresh cadavers, the average distance from the posterior subclavian vein to the subclavian artery was 0.40cm, and the dome of the pleura was 1.75cm posterior to the vein. **CONCLUSION:** Our data suggest that the supraclavicular pocket approach to subclavian vein cannulation is a useful and safe method of adult central venous catheterization, with complication and success rates comparable to more common approaches. The anatomic advantage of a great vein that is closer to the skin and farther from the pleural dome makes this an approach worthy of further investigation.

BACKGROUND

Central venous access is often necessary for the administration of fluids, blood products and certain medications, as well as transvenous cardiac pacing, hemodialysis, and hyperalimentation. In the setting of trauma or CPR, the supraclavicular subclavian vein approach has several potential advantages over the infraclavicular method. Most importantly, it physically removes the clinician from the area where other procedures take place, such as chest compressions or tube thoracostomy. Dronen demonstrated that the supraclavicular approach is easily performed in CPR and has a higher success rate compared to the infraclavicular approach.¹

Yoffa was the first to present a supraclavicular approach to subclavian venipuncture in 1965.² We now present a modification of Yoffa’s original supraclavicular technique for accessing the subclavian vein. Our modification relies on a different set of anatomical landmarks, located medial to the clavicular head of the sternocleidomastoid (SCM), to identify the location for subclavian vein access. We believe that although this modified technique, termed by our group the “pocket approach,” is currently used by clinicians, it has never been formally studied. Indeed, until now, studies that examined the supraclavicular

approach to subclavian central venous access used insertion sites lateral to the SCM.³⁻¹⁶ As noted, the landmarks of the pocket approach are located more medially than in previous descriptions. We believe that our modified approach has all of the benefits of traditional supraclavicular line placement as well as one additional benefit: it eliminates the necessity of moving the patient's head from neutral position.

METHODS

This study had two components. In the first portion we used 24 embalmed and four fresh cadavers to identify the landmarks for the pocket approach to supraclavicular subclavian vein access. The second portion of this study was a retrospective chart review. We measured the success of the pocket approach in adult patients and noted associated complications. We also evaluated the clinical success of this method in the settings of CPR and trauma, as well as in patients with rigid cervical collars.

The initial phase of our study took place in the anatomy lab at the University of California, Irvine (UCI) College of Medicine. The cadavers were obtained with permission from the UCI Willed Body Program in November 2001. Following the study, the cadavers were used for other teaching purposes. Supraclavicular

subclavian vein catheterization was performed in 24 embalmed and four fresh cadavers using the landmarks of the pocket approach to guide needle insertion. These landmarks are located between the sternal and clavicular heads of the SCM. The needle entrance site is located at the midpoint between the sternoclavicular joint and the insertion of the clavicular head of the SCM (Figure 1). This site is located at the inferior border of the triangle formed by the sternal head of the SCM, the clavicular head of the SCM, and the clavicle. Of note, this is also the same triangular region used to access the internal jugular (IJ) vein. However, while the IJ is cannulated at the apex of the triangle, needle insertion for the pocket approach occurs at a more inferior position. Following insertion, the needle is advanced toward the ipsilateral nipple at an angle of 45 degrees to a depth of 1-1.5cm in a caudal direction.

For the purposes of the study, each cadaver was arranged in the supine position and fitted with a stiff cervical collar to maintain the head in neutral position. The collars were kept in place for the entirety of the procedures, and no manipulation of the cervical collars occurred during line placement. Before venipuncture the shoulders were adducted to locate the anatomic landmarks. Venipuncture was performed using equipment from double and triple lumen catheter trays,

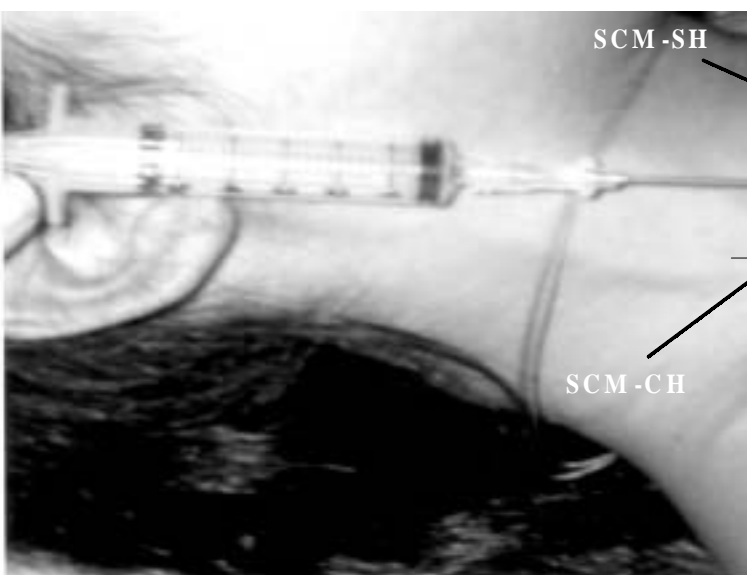


Figure 1. Pocket Approach Landmarks. Anatomic landmarks for the pocket approach (PA) and the traditional lateral approach (LA) for supraclavicular subclavian vein catheterization. The medial and lateral borders of the pocket are marked: sternocleidomastoid muscle sternal head (SCM-SH) and clavicular head (SCM-CH).

and catheter insertion was performed using the standard Seldinger technique.¹⁷ Catheterization was performed at both the left and right pockets; insertion of the catheter took place at the inferior aspect of the triangle, between the sternal and clavicular heads of the SCM when possible. Catheter placement and position was confirmed by dissection of the thoracic cavity. Successful venous cannulation was defined by noting the presence of the catheter in the subclavian or brachiocephalic vein on the right side and the subclavian vein on the left side. In addition, aspiration of either embalming fluid or blood from the catheter was necessary for the procedure to be considered a success. In the 4 fresh cadavers, transverse section allowed for measurements of both the subclavian artery and the pleural dome relative to the position of the subclavian vein. These measurements were not taken in embalmed cadavers, as the relative anatomic relationships were presumed changed by the embalming process.

The second phase of our study took place in a university-based ED with an annual census of 45,000 patients. The ED has an accredited EM residency program and serves as a level-1 trauma center with over 1500 trauma patients annually. Ten EM faculty and 18 EM residents underwent training for the pocket approach on April 3, 2002, followed by faculty supervised hands-on demonstrations during simulated cannulation of the subclavian vein. Following this training session, the charts of consecutive ED patients with attempted supraclavicular line placement were reviewed. Subjects included anyone ≥ 18 years of age who underwent attempted supraclavicular subclavian venous access using the pocket approach.

Charts were identified and the following data were extracted for each procedure: catheter insertion location, technique, number of attempts, reported complications, trauma versus non-trauma patients, presence or absence of a cervical collar, and presence or absence of CPR. Post-procedural chest radiographs were reviewed for the presence or absence of pneumothorax. This chart review was performed between April 4 and August 1, 2002.

The results are reported as frequency percentages with 95% binomial confidence intervals (CI). Distance

The California Journal of Emergency Medicine V:3, Jul-Sep 2004 measurements are reported as means, medians and interquartile ratios (IQR). Data were analyzed using STATA 7.0 (Stata Corporation, College Station, TX). The study protocol was approved by our institutional review board as exempt from the need for written consent under the premises that central line placement is part of the normal pattern of care and that the study entailed both a cadaveric and retrospective chart review protocol.

RESULTS

Supraclavicular subclavian central venous cannulation using the pocket approach was attempted 34 times on 24 embalmed cadavers and four fresh cadavers. Cannulation was successful in all attempts (34/34; 95% CI 90% to 100%). In the 4 fresh cadavers, the mean distance from the posterior border of the subclavian vein to the subclavian artery was 0.40cm (median 0.41cm; IQR 0.36cm to 0.44cm). The dome of the pleura was on average 1.75cm posterior to the vein (median 1.75cm; IQR 1.55cm to 1.90cm).

Chart review identified 68 patients who underwent attempted supraclavicular subclavian central venous access using the pocket approach. Successful cannulation of the subclavian vein was demonstrated in 90% (61/68; 95% CI 80% to 96%). No pneumothoraces were reported (0/68, 95% CI 0% to 5%). Cannulation was achieved on the first attempt in 54% of cases (mean number of attempts 1.5; range 1 to 3). The number of attempts was not recorded in the seven failed cases. Explanations for unsuccessful placement included catheter misplacement in two cases and respiratory distress in another case. No explanation was reported in four cases.

In 11 of the 68 subjects, a stiff cervical collar was in place during central line placement; in all 11 cases, cannulation was successful (95% CI 72% to 100%). In 16 of the 68 patients, line placement was performed while simultaneous CPR was in progress; cannulation was successful in 94% of these patients (15/16; 95% CI 70% to 100%). The success rate in patients not undergoing CPR was 88% (46/52; 95% CI 77% to 96%). In 12 of the 68 subjects, central line placement was performed as part of trauma resuscitation; cannulation was successful in 100% (95% CI 74% to 100%).

DISCUSSION

In 1965 Yoffa presented the first report of the supraclavicular approach to subclavian vein cannulation.² He described the clavisternomastoid angle, formed by the junction of the lateral head of the SCM and the clavicle, as the critical landmark for needle insertion. The technique involved the positioning of a patient's head and neck by elevating and turning the head to one side, which helped to identify the lateral border of the clavicular head of the SCM. In his original report, Yoffa reported a 100% success rate and no serious complications other than slight bleeding at the insertion site. Garcia et al. later fine-tuned the technique to include a more shallow entry and trajectory of the needle.³ They noted that in cadaver dissections it was simpler to aim for the confluence of the subclavian vein and the internal jugular vein. Subsequent case series and one randomized clinical trial demonstrated good success rates and low complication rates with this technique.^{4-12,14-16} MacDonnell et al. described additional modifications of the technique in a cadaver study.¹³ The authors identified the needle insertion point as the junction of the medial and middle thirds of the distance between the sternoclavicular joint and the acromioclavicular joint.

In this current study of the supraclavicular pocket approach, we report a 90% success rate with no cases of iatrogenic pneumothorax. This success rate is comparable to other supraclavicular cannulation methods (ranges 79 to 100%).³⁻¹⁶ Other techniques for subclavian venous access are perhaps more popular because of higher prevalence in the medical literature. Both the infraclavicular and traditional supraclavicular approaches to subclavian venous access have been studied for over 35 years. Nonetheless, the approach described in our study uses simple and easily identifiable anatomic landmarks, is associated with a high success rate, and does not require patient head or neck manipulation. Furthermore, our technique is ideal in CPR and trauma settings, allowing concurrent activities to proceed without placing the clinician in compromising or distracting positions.

Data from the cadaver portion of this current study suggest that a supraclavicular approach to subclavian vein access may have an added advantage based on the anatomy of critical structures. MacDonnell et al. previously demonstrated that the average skin to vein distance in the traditional supraclavicular approach was 4cm (range 0.9 to 5cm).¹³ We demonstrated that the important structures to avoid, namely the subclavian artery and the dome of the pleura, lie an additional 0.4cm and 1.75cm, respectively, posterior to the subclavian vein. We did not record skin to vein distances in the pocket approach, but feel that this distance is likely to be similar to the traditional approach. This suggests that, with the pocket approach, the subclavian vein can be cannulated closer to the skin and farther from complicating structures.

Reports of pneumothoraces associated with supraclavicular subclavian venous access range between 0 and 3% (95% CI 0.1 to 2.9).^{3-12, 14-16} Nessler et al. and Sterner et al. reported a pneumothorax incidence of 0.2% and 0.8%, respectively.^{8,9} Infraclavicular subclavian vein cannulation is associated with a pneumothorax incidence between 1 and 3% (95% CI 0.2 to 3.3).^{8,9}

Our results should be interpreted with the following limitations in mind. The lack of a comparison group means conclusions about superiority of one method over another cannot be drawn. The retrospective assessment of an archival source also makes our findings vulnerable to detection bias. The direction of this bias would tend to falsely inflate the success rate and falsely depress the complication rate. Charts selected for review were chosen from logs kept by the ED residents, and we believe that all charts were identified. This method of chart review may have biased the data in such a way that it inflated the success rate, since physicians, particularly residents, may under-report their failed procedure attempts. These aspects could be addressed in future studies with prospective patient enrollment, randomization to competing approaches to supraclavicular subclavian vein access, prospective procedure identification, and accurate follow-up of any related complications.

Finally, success or failure of a procedure can be confounded by many factors, including patient history

of drug abuse, history of prior central line attempts, physician experience, and urgency of the clinical situation necessitating central venous access. Although specific subsets were considered in this study (CPR, cervical collar, and trauma status), the sizes were too small to make any statements about the effectiveness of the procedure in a particular subgroup. The addition of ultrasound to aid venous access was not considered in this study, but has become a common accessory to central line placement.¹⁸ Our findings should be regarded as pilot data and are not intended to alter clinical practice at this point, despite the current use of this method in emergency medicine. These data do provide the substrate for a prospective, randomised, controlled study of central line methods.

CONCLUSIONS

Based on our preliminary data, the supraclavicular pocket approach to subclavian vein cannulation may be a useful and safe method of adult central venous catheterization with complication and success rates comparable to more common central venous cannulation approaches. There may also be subgroups of patients for which this approach has advantages, especially those requiring multi-person response teams. We feel that the pocket approach is worthy of further investigation.

ACKNOWLEDGEMENTS

Special thanks to Rohini Singh for her assistance with both the cadaver and chart extracting portions of the study.

REFERENCES

1. Dronen S, Thompson B, Nowak R, Tomlanovich M. Subclavian vein catheterization during cardiopulmonary resuscitation. *JAMA* 1982;247:3227-3230.
2. Yoffa D. Supraclavicular subclavian venepuncture and catheterisation. *Lancet* 1965;1:614-617.
3. Garcia JM, Mispireta LA, Pinho RV. Percutaneous supraclavicular superior vena caval cannulation. *Surg Gynecol Obstet* 1972;134:39-841.
4. James PM, Myers RT. Central venous pressure monitoring: misinterpretations, abuses, indications and a new technic. *Ann Surg* 1972;175:693-701.

5. Brahos GJ. Central venous catheterisation via the supraclavicular approach. *J Trauma* 1977;17:872-877.
6. Brahos GJ, Cohen MJ. Supraclavicular central nervous catheterisation: technique and experience in 250 cases. *Wis Med J* 1981;80:36-38.
7. Helmkamp BF, Sanko SR. Supraclavicular central venous catheterisation. *Am J Obstet Gynecol* 1985;153:751-754.
8. Sterner S, Plummer DW, Clinton J, Ruiz E. A comparison of the supraclavicular approach and the infraclavicular approach for subclavian vein catheterisation. *Ann Emerg Med* 1986;15:412-424.
9. Nessler R, Dworzak H, Nagelein HH. Supraclavicular puncture of the anonymous vein. *Anasth Intensivther Notfallmed* 1987;22:232-234.
10. Conroy JM, Rajagopalan PR, Baker JD, Bailey MK. A modification of the supraclavicular approach to the central circulation. *South Med J* 1990;83:1178-1181.
11. Sanchez R, Halck S, Walther-Larsen S, Heslet L. Misplacement of subclavian venous catheters: importance of head position and choice of puncture site. *Brit J Anaesth* 1990;64:632-633.
12. Jones CE, Walters GK. Efficacy of the supraclavicular route for temporary hemodialysis access. *South Med J* 1992;85:725-728.
13. MacDonnel JE, Perez H, Pitts SR, Zaki SA. Supraclavicular subclavian vein catheterization: modified landmarks for needle insertion. *Ann Emerg Med* 1992;21:421-424.
14. Lui K, Hou D, Li X, Jin F. Rapid bedside temporary pacing by the right supraclavicular subclavian vein approach. *Am J Card* 1993;71:1234-1235.
15. Muhm M, Sunder-Plassmann G, Apsner R, Kritzinger M, Heismayr M, Druml W. Supraclavicular approach to the subclavian/innominate vein for large-bore central venous catheters. *Am J Kidney Dis* 1997;30:802-808.
16. Nevarre DR, Domingo OH. Supraclavicular approach to subclavian catheterisation: review of the literature and results of 178 attempts by the same operator. *J Trauma* 1997;42:305-309.
17. Sacchetti AD. Guide-wire (Seldinger) technique for catheter insertion. In: *Clinical Procedures in Emergency Medicine*. 3rd edition. Edited by Roberts JR, Hedges JR. Philadelphia: WB Saunders Company;1998:334-341.
18. Dronen SC, Younger JG. Central venous catheterisation and central venous pressure monitoring. In: *Clinical Procedures in Emergency Medicine*. 3rd edition. Edited by Roberts JR, Hedges JR. Philadelphia: WB Saunders Company;1998:358-385.