

REPORTS

Case Report: An Unusual Case of Sudden Cardiovascular Collapse in an Elderly Adult

Aaron E. Bair, MD¹

Dustin Ballard, MD¹

Michael Thornton, MD²

Ken Y. Yoneda, MD²

¹*Department of Emergency Medicine*

²*Department of Internal Medicine—Division of Pulmonary/Critical Care Medicine University of California, Davis School of Medicine Sacramento, California*

Correspondence:

Aaron E. Bair, M.D.

Assistant Professor

Department of Emergency Medicine.

U.C. Davis, Medical Center,

2315 Stockton Blvd., PSSB #2100

Sacramento, CA 95817

email: aebair@ucdavis.edu

vmail: (916) 734-4051

ABSTRACT

In our report we describe a case of foreign body aspiration leading to arrest. The patient's resuscitation was remarkable for the development of a large pneumothorax and atelectasis of the right lung. Aspiration was suspected and early bronchoscopy was performed. A large grape was found to be obstructing the right main stem bronchus and was retrieved using a bronchoscopic snare. In this case early intervention allowed the removal of the intact grape with subsequent re-expansion of the lung. The technique used for retrieval is described.

INTRODUCTION

We present a case of cardiac arrest in an elderly adult, which was likely precipitated by a foreign body aspiration. In our report we discuss the importance

of addressing the possibility of significant aspiration early in the management course. Additionally, we highlight the importance of early bronchoscopy along with a description of the technique used for removal of the foreign body.

CASE DESCRIPTION

A 90 year-old woman choked and collapsed while standing in line at the local market. No other prodrome was evident to witnesses prior to her collapse. The paramedics reported that upon their arrival the patient was pulseless with a narrow complex on electrocardiographic monitoring with a heart rate in the 50's. The patient was endotracheally intubated and intravenous epinephrine and atropine were administered per paramedic protocol. During her initial resuscitation the paramedics had initiated chest compressions. Total CPR time was estimated to be 10 minutes. Her initial history was limited to the above information given by the paramedics.

Physical examination revealed an elderly female who was orally intubated without any spontaneous respirations. She was afebrile with an initial pulse oximetry recording of 97% despite the administration of 100% oxygen by endotracheal tube. Her initial blood pressure was 140/85 with a heart rate of 98. Her lung sounds were coarse bilaterally. Chest rise was symmetric and no crepitus of her chest wall was noted on physical exam. Heart tones were regular without appreciable murmur or gallop. Her extremities were well perfused. Her initial neurological exam, in the absence of sedation or chemical paralysis, revealed mid range, sluggish pupils without extremity posturing. The remainder of her exam was remarkable for an absence of evident trauma.

Shortly after arrival to the ED she became hypotensive with a systolic blood pressure of 80 mm Hg. A 500 ml bolus of normal saline was administered for her hypotension. An ECG done at this time revealed nonspecific changes that were non-diagnostic for acute myocardial ischemia. The initial portable AP chest x-ray (Figure 1 and 2) revealed a right-sided pneumothorax.

During this time the patient's hypotension worsened. With the recognition of the pneumothorax an urgent thoracostomy tube was placed. No significant rush of air was noted upon entry into the thoracic cavity. However, the patient's blood pressure did improve with the above therapy. Her pulse oximetry measurement was stable in the mid to high 90's throughout her initial resuscitation. A repeat portable chest x-ray was obtained after placement of the chest tube (Figure 3).

Because of the right lung collapse despite an adequate chest tube, the patient underwent flexible video bronchoscopy in the emergency department by the pulmonary/critical care team. The obstructing foreign body, an intact grape, was tightly lodged in the right main bronchus as shown in Figure 4. After discussion with the critical care team it was agreed that the patient should undergo attempts to retrieve the grape while she was still in the ED. Figure 5 demonstrates the placement of a bronchoscopic snare for removal of the grape. Ultimately, the grape was held securely by the snare and withdrawn from the bronchus into the tip of the endotracheal tube. As the grape was too large for removal through the endotracheal tube, the grape was maintained in this position (Figure 6) while the endotracheal tube, grape and bronchoscope were removed simultaneously from the patient (Figure 7). Because of her depressed mental status the patient was then re-intubated to secure her airway. A post-procedure chest x-ray demonstrated complete re-expansion of the right lung (Figure 8).

She remained hemodynamically stable throughout the remainder of her hospitalization. Her cardiac injury markers were normal. However, it was apparent that the initial event had caused a severe hypoxic encephalopathy. In light of her severe brain injury and grim prognosis ventilatory support was ultimately withdrawn.

DISCUSSION

It is likely that the cause of this patient's sudden collapse was a complete airway obstruction from the grape aspiration. Subsequent information indicated that immediately prior to her collapse the patient was noted to be eating something while standing in the

market check-out line. We surmise that the grape was initially in the larynx or trachea and with subsequent intubation and positive pressure became lodged in the right main stem bronchus. Such an impacted obstruction likely contributed to the barotrauma (i.e., pneumothorax) seen in this case by creating an entrapped volume of air. We expect that the brief period of chest compressions against such a volume of trapped air would be sufficient to cause a pneumothorax.

It is important to remember that foreign body aspiration can be rapidly fatal in both children and adults. The pediatric literature highlights the aspiration risks to young children, especially with small, slippery round objects (i.e., nuts, grapes, marbles).¹⁻³ While aspiration is recognized more frequently in children, the term "café coronary" refers to a sudden cardiac arrest after total airway obstruction in adults. Among the adult population such obstructing material is more often comprised of incompletely chewed meat which may obstruct at the level of the glottis or, less likely, in the mid trachea. Adults with swallowing difficulties from neuromuscular processes (e.g., a cerebrovascular insult, Parkinsonism, etc.) are at increased risk for significant aspiration events.

In this case the key diagnostic and therapeutic maneuver was early bronchoscopy. Early removal of the grape not only improved our ability to ventilate the patient but we expect that it made it easier to remove the grape in its entirety. We anticipate that with time the grape would have softened and would have broken apart with attempts at retrieval. In such cases the need for bronchoscopy should be considered early when there is a large amount of unilateral pulmonary atelectasis. Bronchoscopy is more frequently performed after the patient has been stabilized and is in the intensive care unit. However, if the patient is critically unstable it may need to be performed early in the patient's course while still in the ED. In the current era of hospital crowding, patients may also remain in the emergency department well into their "inpatient" stay. As such, even more non-urgent procedures are being done in the ED. Regardless of where the patient is located in the hospital, it is important to recognize

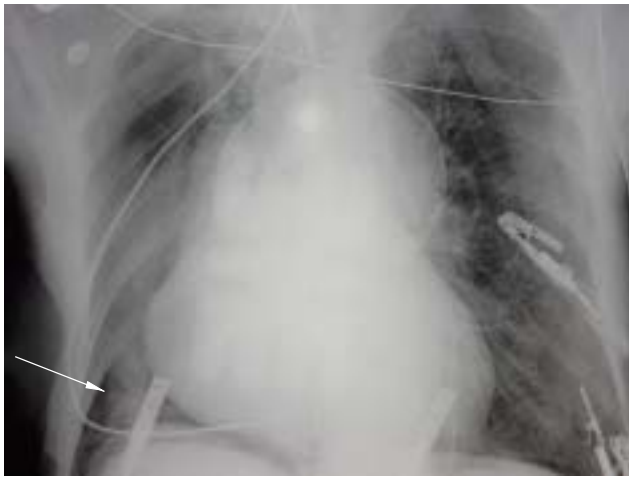

Figure 1. Initial portable chest x-ray. The arrow demonstrates a pleural line consistent with a pneumothorax.

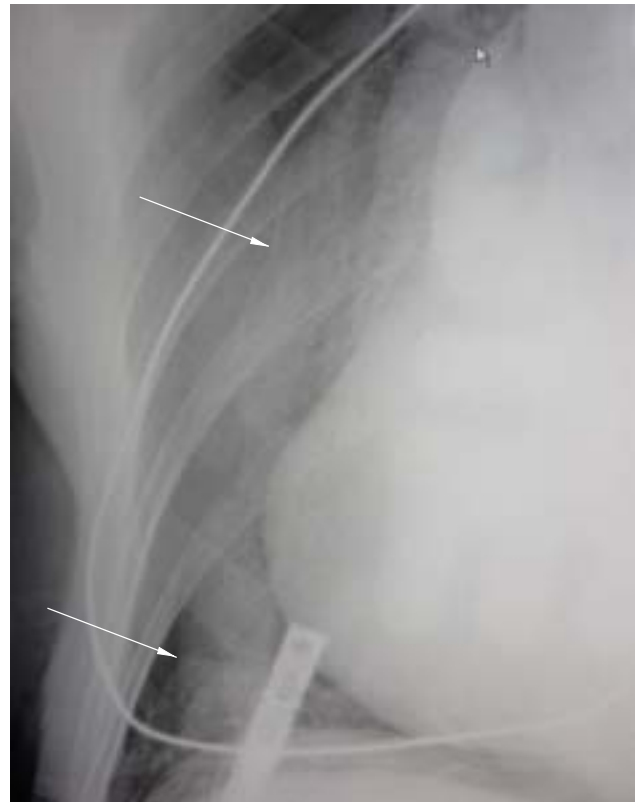

Figure 2. A magnified image of the right side of the patient's chest. The arrows indicate a distinct pleural line.

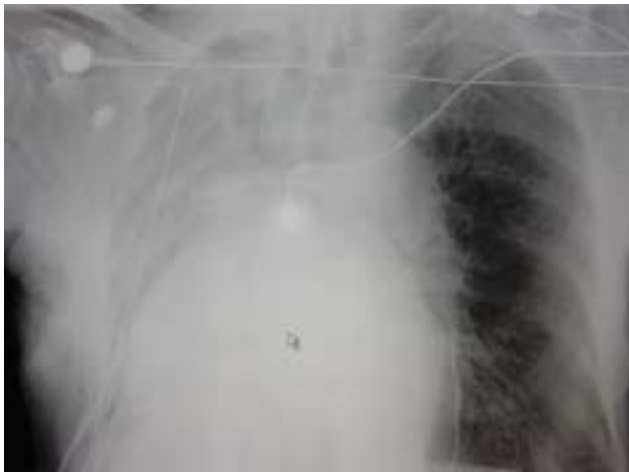

Figure 3. Portable chest x-ray reveals well-placed thoracostomy tube and endotracheal tubes. However, the right lung appears atelectatic and has shifted the mediastinum to the right.

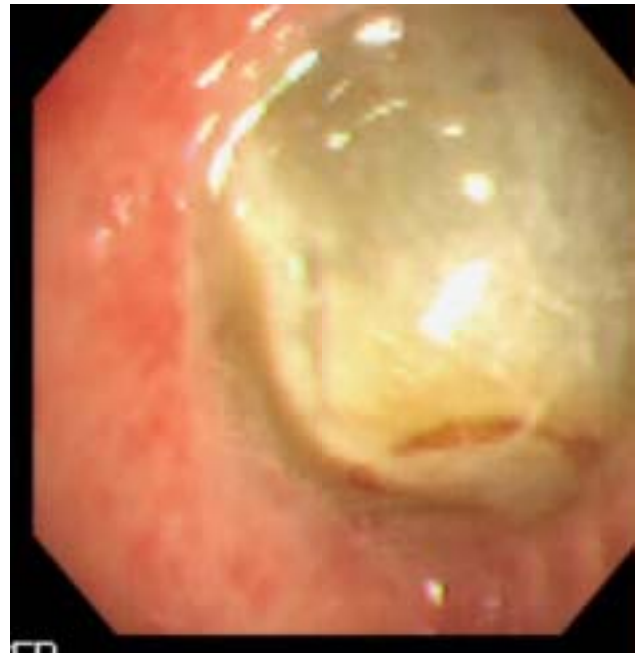

Figure 4. An intact grape obstructing the lumen of the right main bronchus.

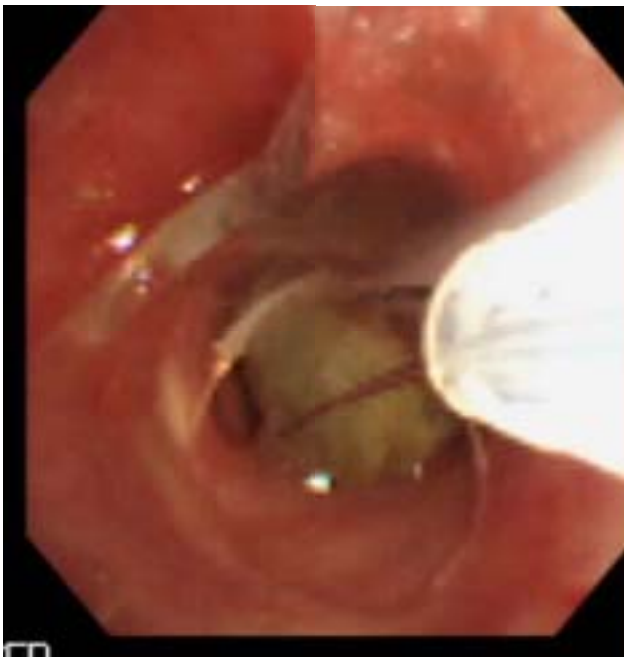

Figure 5. A retrieval snare is placed around the grape.

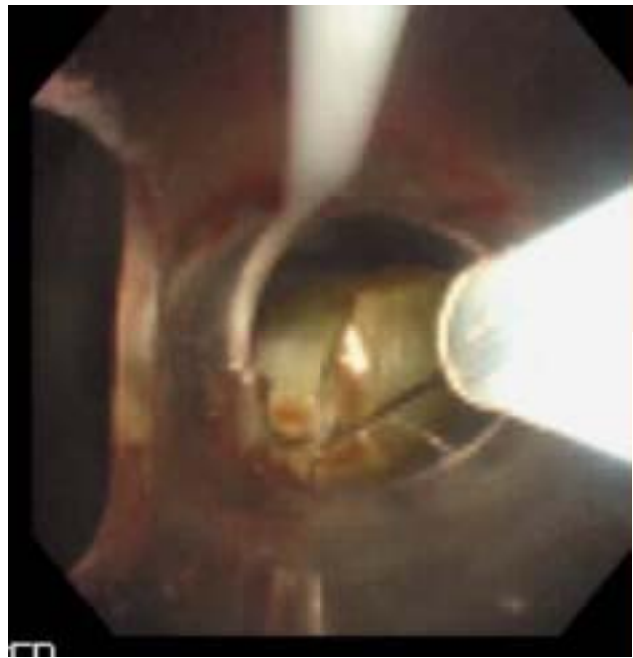


Figure 6. The snare holds the grape in close approximation to the distal end of the endotracheal tube. This position of the tube and ensnared grape was maintained as the endotracheal tube was withdrawn from the airway.

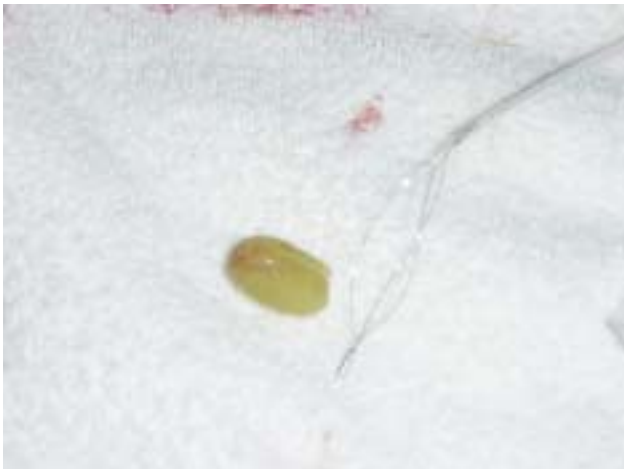

Figure 7. The grape and snare after removal from the patient.

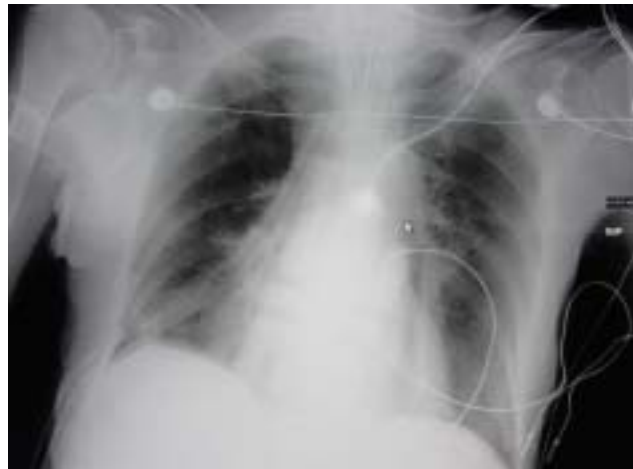

Figure 8. Post-operative chest x-ray revealing complete re-expansion of the right lung after removal of the grape.

the situation when an urgent need may arise for such a diagnostic and potentially therapeutic maneuver.

The technique described here was perhaps novel from the ED perspective. Rigid endoscopes have historically been used to manipulate large foreign bodies as they generally have larger working channels for suction and tool manipulation. However, rigid bronchoscopy is generally performed in the operating suite due to the patient's sedation requirements. However, in our case a flexible video bronchoscope was successfully used to identify and remove a relatively large obstructing foreign body. As we described, the grape was too large to be withdrawn through the endotracheal tube. Instead, we removed the endotracheal tube along with the bronchoscope and ensnared grape. This required the patient to undergo a rapid re-intubation after a brief period of extubation.

We must acknowledge that the etiology of the patient's collapse might have been from something other than a primary aspiration event. However, the initial rhythm, response to therapy and subsequent hospital course all argue against a primary cardiac cause. In addition, the resuscitation priorities and early management would likely remain the same even if she had, in fact, suffered a primary cardiac dysrhythmia or seizure with secondary aspiration.

REFERENCES

1. Berkowitz RG, Lim WK. Laryngeal foreign bodies in children revisited. *Ann Otol Rhinol Laryngol* 2003;112(10):866-8.
2. Kumar P, Athanasiou T, Sarkar PK. Inhaled foreign bodies in children: diagnosis and treatment. *Hosp Med* 2003;64(4):218-22.
3. Robinson PJ. Laryngeal foreign bodies in children: first stop before the right main bronchus. *J Paediatr Child Health* 2003;39(6):477-9.
4. Mittleman RE, Wetli CV. The fatal cafe coronary. Foreign-body airway obstruction. *JAMA* 1982;247(9):1285-8.
5. Enwo ON, Wright M. Sausage asphyxia. *Int J Clin Pract* 2001;55(10):723-4.
6. Aboussouan LS, Stoller JK. Diagnosis and management of upper airway obstruction. *Clin Chest Med* 1994;15(1):35-53.