

Images in Emergency Medicine : CSF Hydrothorax

Nicholas Testa, MD
Sean O. Henderson, MD

Department of Emergency Medicine, Keck School of Medicine of the University of Southern California Medical Center

Submission history: Submitted May 24, 2007; Accepted June 7, 2007.
Reprints available through open access at www.westjem.org
[WestJEM. 2007;8:96.]

A 30-year-old African-American female presented to the Emergency Department with a complaint of a cough for two months. The patient had a history of developmental delay, seizure disorder and ventriculo-peritoneal (VP) shunt. Physical exam was significant for a blood pressure at 101/71 mm Hg, heart rate at 111 beats per minute, respiratory rate at 18 breaths per minute and temperature of 98° F. She was a well-developed female in no apparent distress with a shunt palpable on the left side of the skull and a normal lung exam, except for slightly decreased breath sounds in the left base. During her workup, a chest x-ray demonstrated a large left-sided pleural effusion (Figure 1). The patient received a thoracentesis and the fluid was initially thought to be a transudate.

Subsequent CT scan of the chest revealed the tip of the VP shunt in the left chest adjacent to the aorta resulting in a CSF hydrothorax (Figure 2). Thoracic migration of peritoneal catheters causing hydrothorax is a rare complication of VP shunts.¹ In some cases the migration of the catheter results in malfunction and neurologic findings, which was not the case in our patient.²

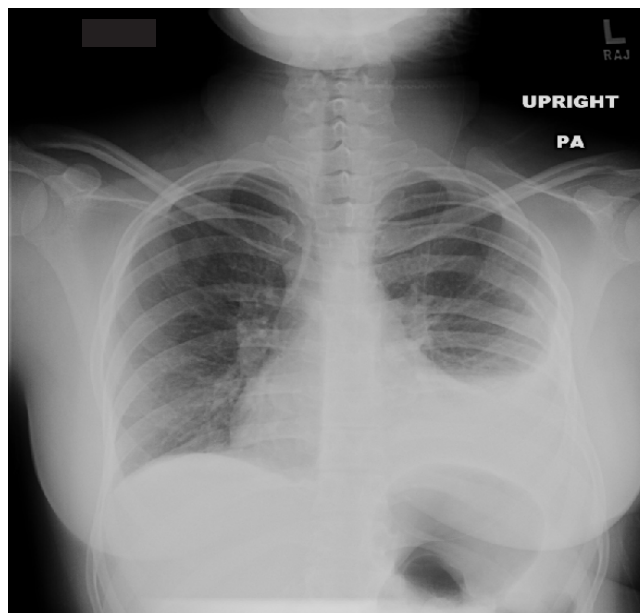


Figure 1. Chest x-ray demonstrating a left-sided pleural effusion.

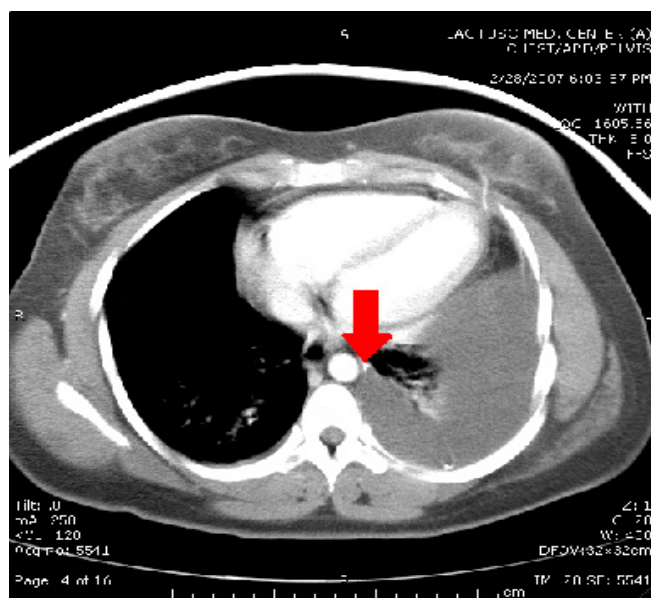


Figure 2. Computed tomography chest demonstrating the tip of the ventriculo-peritoneal shunt catheter adjacent to the aorta.

Address for Correspondence: Sean O. Henderson, MD
Department of Emergency Medicine LAC+USC Medical Center
Unit #1, Room 1011 1200 N. State St. Los Angeles, CA 90033

REFERENCES

1. Hadzikaric N, Masser M, Mashani A, Ammar A. CSF Hydrothorax – VP Shunt complication without displacement of a peritoneal catheter. *Child's Nerv Syst.* 2002; 18:179-182.
2. Gan YC, Steinbok P. Migration of the peritoneal tip of a ventriculoperitoneal catheter causing shunt malfunction. *J Neurosurg. (2 Suppl Pediatrics).* 2006;105:153.