

# Images in Emergency Medicine : Retropharyngeal Abscess

Corey McLeod, MD  
Kristi A. Stanley, BA

Department of Emergency Medicine, LAC+USC Medical Center

Submission history: Submitted May 8, 2007; Accepted June 18, 2007.  
Reprints available through open access at [www.westjem.org](http://www.westjem.org)  
[WestJEM. 2008;9:55.]

A 40-year-old female presented to the emergency department with a one-week history of URI symptoms and a one-day history of more severe throat pain and swelling. Upon physical examination the patient was afebrile and although she did not demonstrate any signs of respiratory distress, examination of her neck revealed fullness on the right. A lateral plain film of the neck showed soft tissue swelling anterior to the vertebral bodies (Figure 1) and a CT scan demonstrated fluid in the retropharyngeal space and an abscess. Fiberoptic laryngoscopy was performed and the airway was found to be swollen and compromised. The patient was taken to the operating room for an awake tracheostomy, the abscess was incised and drained, and she was admitted for overnight observation.

Despite the advent of antibiotics and improvement of dental hygiene, deep space neck infections persist as a cause of morbidity and mortality. Retropharyngeal abscess (RPA) is an ENT emergency due to the possibility of life-threatening airway complications.<sup>1</sup> Patients with RPA typically have localized symptoms of dysphagia, voice changes, odynophagia, trismus, and neck/jaw pain.<sup>2</sup> Generalized symptoms of fever, chills, and loss of appetite may be present as well. Indicators of RP abscess during the physical exam are stridor, shortness of breath, drooling, cervical lymphadenopathy, and bulging of the pharyngeal wall.<sup>3</sup> Lateral radiographs will manifest with preveterbral air/fluid levels or abnormal widening of the preveterbral soft tissue, normally 5 – 7 mm wide at the level of the second cervical vertebrae.<sup>2</sup> Treatment in the Emergency Department should focus primarily on ensuring a patent airway. Oral intubation may be compromised by a large abscess or in turn may lead to rupture of the abscess, so ENT should be consulted for emergency tracheostomy. Antibiotic choices include high-dose penicillin plus metronidazole, piperacillin/tazobactam, ampicillin/sulbactam or ticarcillin/clavulanate.<sup>2</sup>

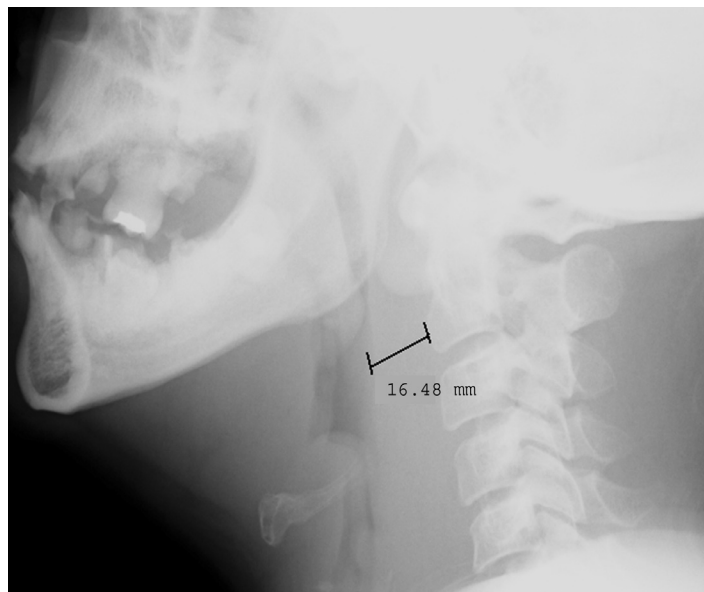


Figure.

Address for correspondence: Kristi Stanley BA,  
Department of Emergency Medicine, LAC+USC Medical Center,  
Unit #1, Room 1011, 1200 N. State St., Los Angeles, CA 90033.

## REFERENCES

1. Wang LF, Kuo WR, Tsai SM, Huang KJ. Characterizations of life-threatening deep cervical space infections: a review of one hundred ninety-six cases. *American Journal of Otolaryngology*. 2003; 24:111-7.
2. Calder K and Ruben J. Ophthalmologic Emergencies. In: Henderson SO, ed. *Emergency Medicine*. Georgetown, TX: Landes Bioscience; 2006:372-373.
3. Marra S, Hotaling AJ. Deep neck infections. *American Journal of Otolaryngology*. 196; 17:287-298.