

Images in Emergency Medicine: Chemical Pneumonitis from Hydrocarbon Aspiration

Keimanh Pham, MD
James Sverchek, MD
Rick A. McPheeters, DO

Kern Medical Center, Department of Emergency Medicine

Supervising Section Editor: Eric R. Snoey, MD

Submission history: Submitted December 28, 2007; Revision Received February 28, 2008; Accepted March 13, 2008.

Reprints available through open access at www.westjem.org

[WestJEM. 2008;9:165.]

A three-year-old female presented to the emergency department (ED) with a chief complaint of choking for 20 minutes after ingestion of an unknown clear liquid; this was followed by one episode of emesis. On arrival she had no respiratory distress, and her symptoms had resolved. Her physical exam and vital signs were unremarkable with a room air oxygen saturation of 99% and a respiratory rate of 28 breaths per minute. The patient's family brought in the water bottle containing the clear substance, and it was identified as naphtha. An initial chest radiograph showed no infiltrates or consolidations. The patient was given nebulized saline and did not require further therapeutic intervention.

A repeat chest radiograph (Figure 1) was done four hours after the first, and it showed left lower lobe and right middle lobe infiltrates, demonstrating significant pneumonitis. Throughout her stay in the ED, she continued to have no respiratory distress, auscultation of her chest remained clear, and her vital signs normal. Nevertheless, the patient was admitted to pediatrics for observation. Her hospital stay was uneventful and she was discharged home in 24 hours after a final chest radiograph showed no interval changes.

Exposure to hydrocarbons comes in many forms, but it causes the most damage with aspiration.¹ This damage depends on the viscosity (the resistance to flow, measured in Saybolt seconds universal [SSU]); volatility (the propensity to vaporize); and the chemical side chains of the hydrocarbon. Lower viscosity, especially less than 60 SSU, and higher volatility are associated with a greater chance of aspiration with resultant pulmonary injury.²

While hydrocarbons have been reported to be toxic to various organ systems, the most frequent adverse effect is aspiration, which can cause a chemical pneumonitis from direct injury to the lung parenchyma.³ Other effects of aspiration are pulmonary edema, bronchospasm, and resultant hypoxia. On pathology, there is a necrotizing pneumonia along with direct destruction of capillaries, alveolar septae, and the pulmonary epithelium. The surfactant layer, which is composed of lipids, is made soluble by hydrocarbons, causing further damage. Subsequently, there can be atelectasis, interstitial inflammation, and hyaline membrane formation.

Patients with hydrocarbon exposure should be placed on a cardiac monitor with continuous pulse oximetry. A chest radiograph should be taken in patients with significant exposure or if they are symptomatic (tachycardia, tachypnea, hypoxia). If

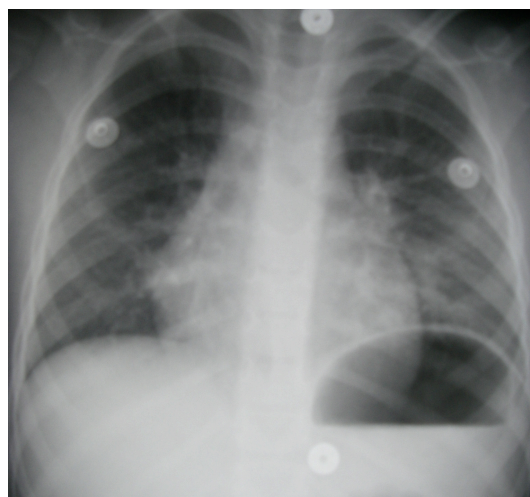


Figure 1.

aspiration is severe, patients may need intubation and positive pressure ventilation.

With minimal exposure, patients can be discharged after a six-hour period of observation. Pulse oximetry and a chest radiograph may be helpful in reassessing the patient before discharge. Symptomatic patients with more severe exposure should be admitted and observed for a minimum of 24 hours.

Address for Correspondence: Keimanh Pham, MD, Department of Emergency Medicine, Kern Medical Center, 1830 Flower Street, Bakersfield, CA 93308. Email: kiemanh@gmail.com.

REFERENCES

1. Lee DC. Hydrocarbons. Marx JA *et al.* (eds): Rosen's Emergency Medicine: Concepts and Clinical Practice, ed 6, 2006, pp2428-32.
2. Dyer S. Hydrocarbons. Wolfson AB, *et al.* (eds): Harwood-Nuss' Clinical Practice of Emergency Medicine, ed 4, 2005, pp1590-93.
3. Wax PM, Beuhler MB. Hydrocarbons and Volatile Substances. Tintinalli JE, *et al.* (eds): Emergency Medicine: A Comprehensive Study Guide, ed 6, 2004, p1124-30.