

Tension Pyothorax Causing Cardiac Arrest

Terence L. Ahern, BA*
Gregg A. Miller, MD†

* Keck School of Medicine of the University of Southern California
† Harbor-UCLA, Department of Emergency Medicine

Supervising Section Editor: David E. Slattery, MD

Submission history: Submitted April 28, 2008; Revision Received September 16, 2008; Accepted October 13, 2008.

Reprints available through open access at www.westjem.org

[WestJEM. 2009;10:61.]

A 28-year-old woman was seen by an emergency physician for flu-like symptoms and discharged home with a presumptive viral syndrome. A week later, she was readmitted to the emergency department by ambulance in severe respiratory distress. She presented with a blood pressure of 78/42 mm Hg, heart rate at 120 beats per minute, respirations at 50 per minute, a temperature of 103.3 degrees Fahrenheit, and pulse oximetry at 50% on room air. Breath sounds were decreased on the right, and a portable chest radiograph showed a collapsed right lung and congested right pleural cavity with a massive mediastinal shift to the left side (Figure 1). The patient's airway was secured by endotracheal intubation due to severe hypoxia and the radiograph findings of a large effusion. Minutes after intubation, the patient deteriorated to cardiac arrest. The combination of IV fluids, chest compressions, and two rounds of atropine and epinephrine elicited no hemodynamic response. Concomitant emergency needle thoracostomy was performed on the right and then the left chest with a 14-gauge cannula, but the patient did not respond. Considering the possibility of a tension pyothorax, the decision was made to perform a tube thoracostomy on the right chest. Immediately upon dissection through the pleura, purulent fluid began draining under pressure and the patient instantly experienced the return of spontaneous circulation. A total of 1500-2000 ml of purulent exudate was drained, and her condition continued to stabilize until transfer to the ICU. She was later diagnosed as HIV positive.

Tension pyothorax is rare and may occur as a complication of pneumonia or lung abscess.¹ Although the accumulation of gas is the most common cause of an expanding interpleural space, the presence of other substances (hydrothorax, hemothorax, chylothorax, and pyothorax) under pressure may be sufficient to cause hemodynamic and respiratory compromise. Tension pyothorax occurs when a large volume of purulent fluid evokes an inflammatory and fibrotic response that entraps the lung and shifts the mediastinal organs including the heart, lungs, and trachea. Increased intrathoracic pressure can reduce venous return with secondarily decreased cardiac output, and mediastinal deviation can compress the contralateral lung, leading to an emergent situation.² The typical clinical presentation of pyothorax includes fever, tachycardia, cough, dyspnea, and chest pain. Emergency treatment entails the drainage of fluid through a chest tube.³ Risk factors for pyothorax include age (more likely in children and the elderly), male sex, chronic obstructive

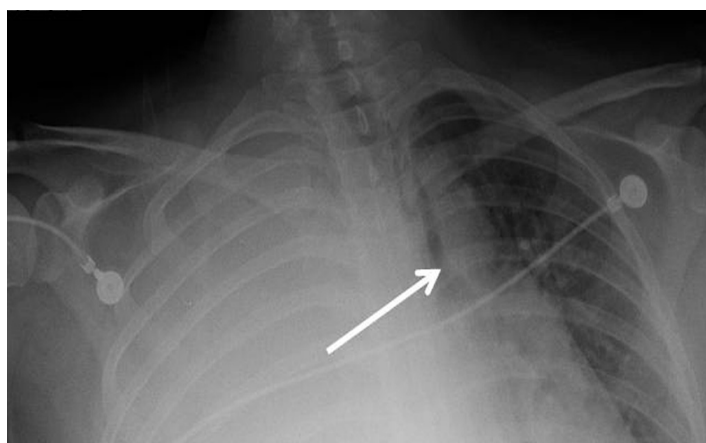


Figure 1. Portable chest radiograph reveals a right pyothorax with a mediastinum that is drastically shifted to the left.

pulmonary disease, diabetes, alcoholism, pneumonia requiring hospitalization, and an immune-compromised host.^{1,2} In this case, the patient was HIV positive. Pyothorax is a more frequent complication of respiratory tract infections in patients with HIV and its incidence may approach 5.4%.⁴ Additionally, HIV patients often have more complex cases that require surgery with lung resection, multiple antibiotics, and longer periods of chest tube drainage.⁴ Given the serious progression and evolving nature of this case, it seems reasonable to consider tension pyothorax as a cause of emergent cardio-respiratory arrest.

Address for Correspondence: Terence L. Ahern, BA, Department of Emergency Medicine, LAC + USC Medical Center, 1200 State Street, Room 1011 Los Angeles, CA 90032. Email: tahern@usc.edu.

REFERENCES

1. Bramley D, Dowd H, Muwanga C. Tension empyema as a reversible cause for cardiac arrest. *Emergency Medicine Journal*. 2005; 22:919-920.
2. Whiteman PJ, Wilson MT, Barcay D, Ting PP, Chen SC. Tension pyopneumothorax in a child: a case report. *The Journal of Emergency Medicine*. 2003; 24:429-431.
3. Sahn SA. Diagnosis and management of parapneumonic effusions and empyema. *Clinical Infectious Diseases*. 2007; 45:1480-1486.
4. Khwaja S, Rosenbaum DH, Paul MC, et al. Surgical treatment of thoracic empyema in HIV-infected patients: severity and treatment modality is associated with CD4 count status. *Chest*. 2005; 128:246-249.