

Painful Red Eye

Travis R. Eastin, MD
Lee G. Wilbur, MD
Rawle A. Seupaul, MD

Indiana University School of Medicine, Department of Emergency Medicine

Supervising Section Editor: Sean O. Henderson, MD
Submission history: Submitted March 23, 2009; Accepted April 20, 2009.
Reprints available through open access at www.westjem.org
[WestJEM. 2009;10:e9.]

A 27-year-old man presented to the emergency department (ED) with a complaint of left eye pain and redness for three days. The eye was initially watery and pruritic and a day later had become completely red and painful. He had no vision changes or antecedent trauma and denied any constitutional or upper respiratory symptoms. Vital signs were normal. The left upper eyelid showed ecchymosis. Pupils were equal and reactive. Visual acuity was 20/25 in both eyes. There was no fluorescein uptake and the remainder of the slit lamp exam was unremarkable.

DIAGNOSIS

Acute hemorrhagic conjunctivitis. Hemorrhagic conjunctivitis is a variant of viral conjunctivitis caused by Coxsackie and enterovirus. It is usually found in tropical regions, where outbreaks are common. Clinically, it is a rapidly progressive, painful conjunctivitis that begins with conjunctival petechiae that coalesce into subconjunctival hemorrhages. Swelling and induration of the eyelids are common. The diagnosis is based on clinical findings, and no specific treatment is available. Symptoms typically resolve within one week. While complications are rare, bacterial superinfection has been reported in the setting of topical steroid use and should therefore be avoided.¹

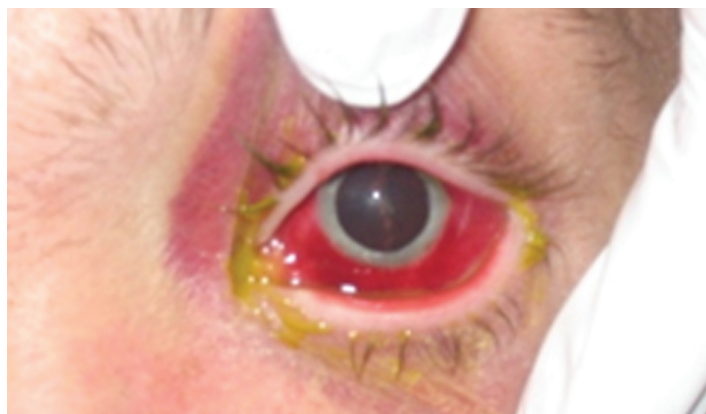


Figure.

Address for Correspondence: Travis Eastin, MD, Department of Emergency Medicine, Indiana University School of Medicine, 1701 N. Senate Blvd., Rm B401, Indianapolis, IN 46202. Email teastin@iupui.edu.

REFERENCES

1. Wright PW, Strauss GH, Langford MP. Acute hemorrhagic conjunctivitis. *Am Fam Physician.* 1992; 45:173-8.