

## Pain in the Neck: the Enigmatic Presentation of an Embedded Acupuncture Needle

Joyce M. Chaput, MD\*  
Troy Foster, MD\*

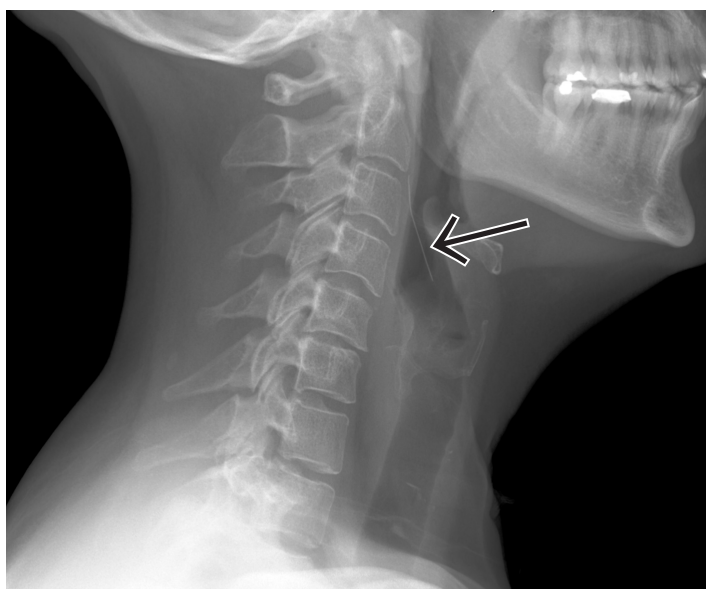
\* University of Chicago, Department of Emergency Medicine, Chicago, IL

Supervising Section Editor: Sean Henderson, MD

Submission history: Submitted June 26, 2009; Revision Received December 7, 2009; Accepted December 29, 2009

Reprints available through open access at [http://escholarship.org/uc/uciem\\_westjem](http://escholarship.org/uc/uciem_westjem)

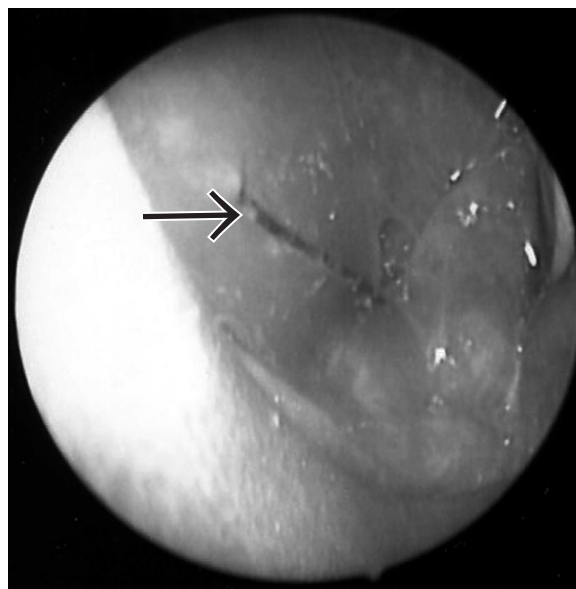
[West J Emerg Med. 2010; 11(2):144-145.]



**Figure 1.** Lateral soft tissue neck radiograph revealing a needle-shaped foreign body.

A healthy 46-year-old female presented to the emergency department (ED) with the complaint of a foreign body sensation in her throat. Patient stated that she was eating a hamburger and chips for lunch when she acutely felt “a piece of a potato chip” lodge in her throat. Although she complained of difficulty swallowing, she was able to tolerate oral intake. She denied any shortness of breath or chest pain. On exam, the patient’s vital signs were stable and she was well-appearing, in no distress. Soft tissue neck radiograph revealed a needle-shaped metallic foreign body. This raised a very concerning question of how the needle got there and whether it had been intentionally placed in the food by the patient or another party intending harm.

A bedside fiberoptic laryngoscopy performed by the on-call ENT surgeon showed an embedded 3.3 cm metallic foreign body lodged in her right piriformis sinus, and she was taken to the operating room for removal. Direct



**Figure 2** Fiberoptic laryngoscopy shows a 3.3 cm metallic foreign body in the esophagus.

laryngoscopy confirmed that the foreign body was an acupuncture needle and that it had not been swallowed but extruded from the wall of the esophagus into the piriformis sinus.

Upon further questioning, the patient said she had acupuncture therapy in an alternative medicine clinic to treat whiplash-associated neck pain after a car accident. This therapy, in which the acupuncturist had placed needles in the back of her neck, occurred six months prior to her presentation to the ED. She did not recall whether one of the needles had broken, but after the procedure she continued to have pain in the neck. For six months until the ED diagnosis, she blamed the car accident for her chronic neck pain.

In general, acupuncture is considered safe. The most common reactions are bleeding, needle pain and skin infections, and vagally mediated systemic symptoms, such as nausea, vomiting and syncope.<sup>1-3</sup> In the literature, a few case

reports have described more serious complications associated with this practice of medicine, such as pneumothorax, cardiac tamponade and spinal cord injury.<sup>2</sup> Although these are significant adverse problems, it should be noted that these complications are rare. For example, pneumothorax occurred only twice in almost 250,000 treatments.

This case describes another rare, potentially hazardous complication associated with acupuncture, in which a broken part of the acupuncture needle was inadvertently left in the patient's skin and migrated through into her hypopharynx. If the needle had not been identified, it could have led to further complications, such as esophageal laceration, esophageal perforation, vascular injuries, mediastinitis<sup>4</sup> or pulmonary aspiration. This case represents a rare complication with acupuncture therapy.

---

*Address for Correspondence:* Joyce M. Chaput, MD, Department of Emergency Medicine, University of Chicago 5841 S. Maryland Ave., Chicago, IL 60637. Email [jljibunao@gmail.com](mailto:jljibunao@gmail.com)

---

#### REFERENCES

1. Lao L, Hamilton GR, Fu J, et al. Is acupuncture safe? A systematic review of case reports. *Altern Ther Health Med*. 2003; 9:72.
2. Ernst E, White AR. Prospective Studies of the safety of acupuncture: a systematic review. *Am J Med*. 2001; 110:481.
3. White A, Hayhoe S, Hart A, et al. Adverse events following acupuncture: prospective survey of 32000 consultations with doctors and physiotherapists. *BMJ*. 2001; 323:485-486.
4. Digbooy GP. Diagnosis and Management of Upper Aerodigestive Tract Foreign Bodies. *Otolaryngol Clin North Am*. 2008; 41:485-496.