

Impending Airway Compromise due to Cystic Hygroma

Giora Weiser, MD*
Nira Beck-Razi, MD†
Itai Shavit, MD*

* Rambam Health Care Campus, Meyer Children's Hospital, Rambam Health Care Campus, Haifa, Israel
† Rambam Health Care Campus, Department of Medical Imaging, Haifa, Israel

Supervising Section Editor: Sean Henderson, MD

Submission history: Submitted January 1, 2011; Revision received January 14, 2011; Accepted February 7, 2011

Reprints available through open access at http://escholarship.org/uc/uciem_westjem

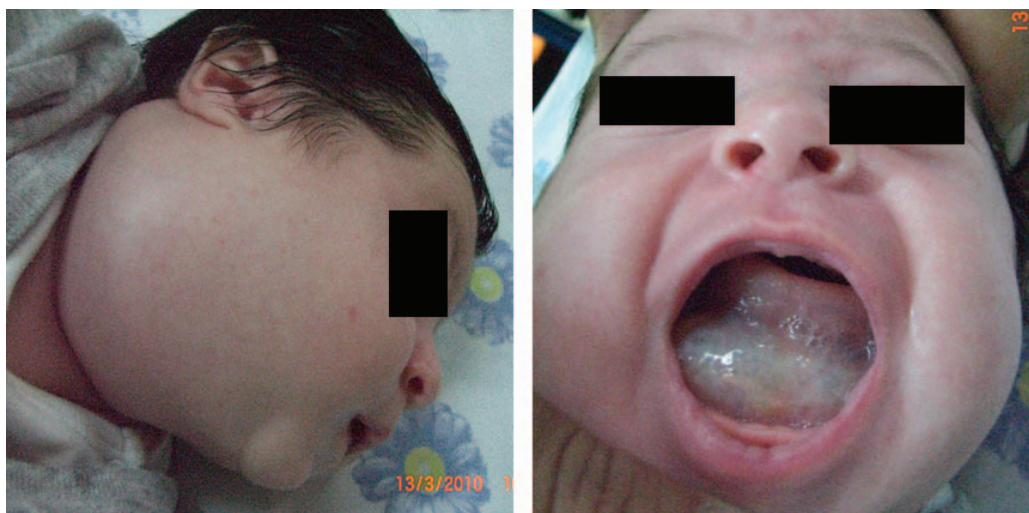DOI: 10.5811/westjem.2011.2.2170

We report on a 3-month-old infant, who arrived in the pediatric emergency department (ED) with a cervical cystic hygroma causing an impending compromise of the airway. We recognize that such a lesion can rapidly progress, and the judicious use of imaging in the ED may help to avoid airway compromise and possibly fatal complications. [West J Emerg Med. 2011;12(4):368–369.]

A 3-month-old boy, who was diagnosed after birth as having a cystic hygroma, was referred to the emergency department (ED) for further evaluation. The baby had no signs of respiratory distress, but a large lesion was noticed on the right neck, emerging from the base of the tongue and threatening the airway patency (Figure 1). Ultrasound examination revealed a large cystic lesion insinuating around

the normal structures of the neck on both sides without compressing the airway (Figure 2). The patient was admitted for further evaluation, and a prophylactic tracheotomy was performed. Unfortunately, the baby died at home 2 months later because of tracheotomy tube-related complications.

Lymphatic malformations are a group of vascular malformations that are usually benign in their behavior. Cystic



A

B

Figure 1. A, Cystic hygroma on the right side of the neck. B, The lesion is infiltrating the oral cavity and displacing the tongue upward.

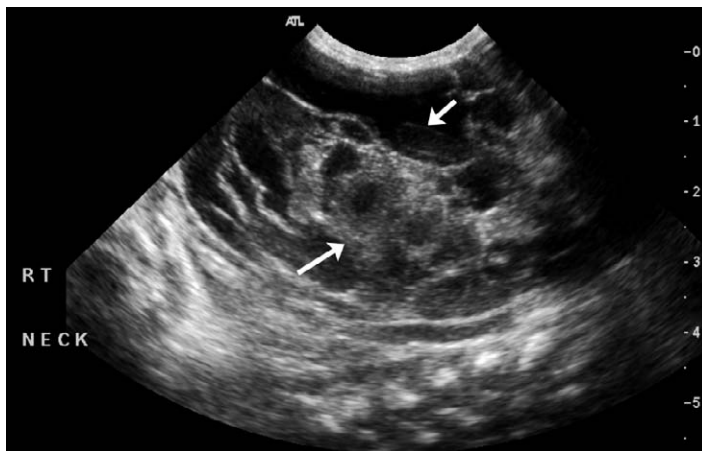


Figure 2. Sonographic longitudinal view of the right neck. A large mass is seen (arrows), insinuating around the normal structures of the neck. The mass is partially anechoic (cystic) and partially shows mixed echogenicity with septae of variable thickness.

hygroma, the largest and most extensive lymphatic malformation, is diagnosed at birth in 40% of the cases.¹ Cystic hygromas usually involve the head and neck, and their course is indolent in most cases.^{1,2} However, these lesions may hemorrhage, develop inflammation or infection, or may progressively enlarge, leading to an expanding lesion that may physically compress local organs.³ Surgical excision is regarded as the treatment of choice; however, when radical excision is surgically challenging, the patient will be treated with sclerotherapy, an injection of a sclerosing substance such as OK432 into the lesion.^{4,5} Sclerotherapy is problematic in cases of airway compromise because of the additional edema that may develop.^{4,5} Presentation of an emergency airway compromise due to a cervical cystic hygroma is usually uncommon, but the emergency physician must be aware that any child with a large cystic lesion may have a massive infiltrating hygroma with a much greater internal involvement of local organs and tissues surrounding the larynx.⁶⁻⁸ Ultrasonography is a readily available technique in the ED, and

we recommend using this modality to evaluate the extensiveness of such a lesion.

Address for Correspondence: Itai Shavit, MD, Rambam Health Care Campus, Meyer Children's Hospital, Department of Emergency Medicine, 6 Ha'Aliya St, PO Box 9602, Haifa 31096, Israel. E-mail: itai@pem-database.org.

Conflicts of Interest: By the WestJEM article submission agreement, all authors are required to disclose all affiliations, funding sources, and financial or management relationships that could be perceived as potential sources of bias. The authors disclosed none.

REFERENCES

1. Fordham LA, Chung CJ, Donnelly LF. Imaging of congenital vascular and lymphatic anomalies of the head and neck. *Neuroimaging Clin North Am.* 2000;10:117–136.
2. Sannoh S, Quezada E, Merer DM, et al. Cystic hygroma and potential airway obstruction in a newborn: a case report and review of the literature. *Cases J.* 2009;2:48.
3. Thompson DM, Kasperbauer JL. Congenital cystic hygroma involving the larynx presenting as an airway emergency. *J Natl Med Assoc.* 1994;86:629–632.
4. Perkins JA, Manning SC, Tempero RM, et al. Lymphatic malformations: review of current treatment. *Otolaryngol Head Neck Surg.* 2010;142:795–803.
5. Luzzatto C, Midrio P, Tchaprassian Z, et al. Sclerosing treatment of lymphangiomas with OK-432. *Arch Dis Child.* 2000;82:316–318.
6. Ishaq M, Minhas MR, Hamid M, et al. Management of compromised airway due to unusual presentation of cystic hygroma. *J Pak Med Assoc.* 2006;56:135–137.
7. Barrand KG, Freeman NV. Massive infiltrating cystic hygroma of the neck in infancy. *Arch Dis Child.* 1973;48:523–531.
8. Sheth S, Nussbaum AR, Hutchins GM, et al. Cystic hygromas in children: sonographic-pathologic correlation. *Radiology.* 1987;162:821–824.