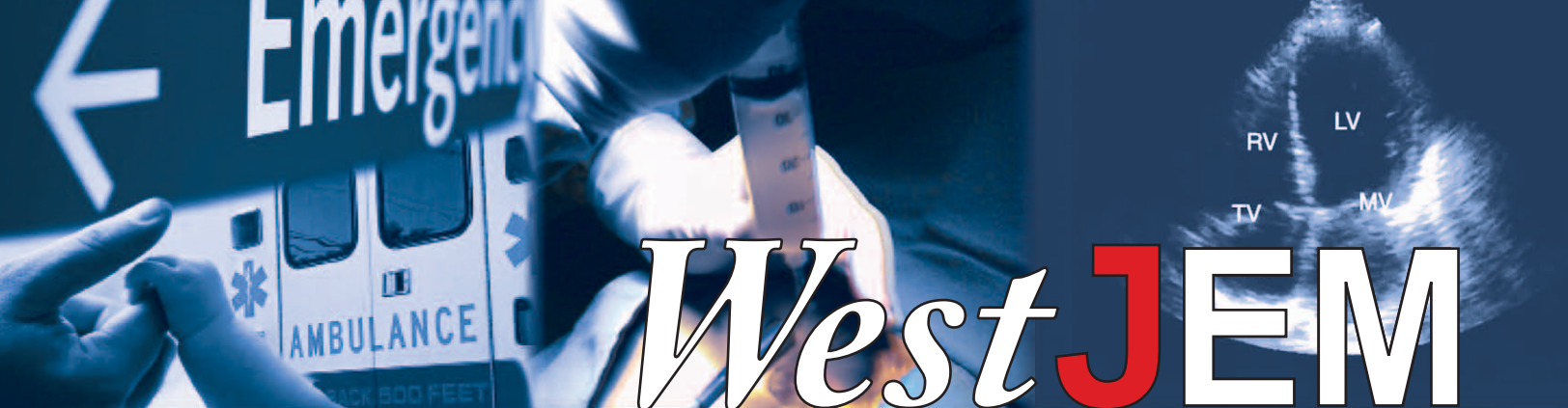



WestJEM

Volume XII, Number 4, November 2011

Open Access at www.westjem.org

ISSN 1936-900X

Western Journal of Emergency Medicine

A Peer-Reviewed Professional Journal

AIRWAY


- 365 Rapid Sequence Intubation from the Patient's Perspective** (Brief Research Report)
D Kimball, RC Kincaide, C Ives, S Henderson
- 368 Impending Airway Compromise due to Cystic Hygroma** (Images in Emergency Medicine)
G Weiser, N Beck-Razi, I Shavit
- 370 Quincke's Disease** (Images in Emergency Medicine)
W Johnson, N Shastri, M Fowler

CLINICAL PRACTICE

- 371 Myositis Ossificans** (Images in Emergency Medicine)
TY Chuah, TP Loh, HY Loi, KH Lee
- 372 Nonconvulsive Status Epilepticus in Hepatic Encephalopathy** (Case Report)
P Jhun, H Kim
- 375 Antibiotic Prescribing Practices of Emergency Physicians and Patient Expectations for Uncomplicated Lacerations** (Original Research)
S Ong, GJ Moran, A Krishnadasan, DA Talan
- 381 Comparison of Three Aspirin Formulations in Human Volunteers** (Original Research)
SP Nordt, RF Clark, EM Castillo, DA Guss
- 386 Reversal of Warfarin-Induced Hemorrhage in the Emergency Department** (Review)
M Zareh, A Davis, S Henderson
- 393 Tattoos and Piercings: A Review for the Emergency Physician** (Review)
M Urdang, JT Mallek, WK Mallon
- 399 Propofol and Etomidate are Safe for Deep Sedation in the Emergency Department** (Review)
MA Denny, R Manson, D Della-Giustina
- 404 Ileus and Small Bowel Obstruction in an Emergency Department Observation Unit: Are There Outcome Predictors?** (Brief Research Report)
ST Dorsey, ET Harrington, WF Peacock IV, CL Emerman



CALIFORNIA ACEP
AMERICAN COLLEGE OF EMERGENCY PHYSICIANS



Western Journal of Emergency Medicine

Table of Contents,

continued

CARDIOVASCULAR

- 408 Prehospital 12-Lead Electrocardiogram within 60 Minutes Differentiates Proximal versus Nonproximal Left Anterior Descending Artery Myocardial Infarction** (Original Research)
RA Aertker, CM Barker, HV Anderson, AE Denktas, GM Giesler, VR Julapalli, JF Ledoux, DE Persse, S Sdringola, MT Vooletich, JJ McCarthy, RW Smalling
- 414 Cardiac Complications in Acute Ischemic Stroke** (Original Research)
CR Wira III, E Rivers, C Martinez-Capolino, B Silver, G Iyer, R Sherwin, C Lewandowski
- 421 Course of Untreated High Blood Pressure in the Emergency Department** (Original Research)
JJ Cienki, LA DeLuca, DJ Feaster
- 426 Vascular Pedicle Width on Chest Radiograph as a Measure of Volume Overload: Meta-Analysis** (Original Research)
H Wang, R Shi, S Mahler, J Gaspard, J Gorchynski, J D'Etienne, T Arnold
- 433 “Playboy Bunny” Sign of Congestive Heart Failure** (Images in Emergency Medicine)
A Hokama, S Arakaki, D Shibata, T Maeshiro, F Kinjo, J Fujita
- 435 Pharmaceutical Sponsorship Bias Influences Thrombolytic Literature in Acute Ischemic Stroke** (Review)
RP Radecki

TECHNOLOGY AND EDUCATION

- 442 Can Emergency Medicine Residents Reliably Use the Internet to Answer Clinical Questions?** (Original Research)
R Krause, R Moscati, S Halpern, DG Schwartz, J Abbas
- 448 Completeness and Accuracy of Emergency Medical Information on the Web: Update 2008** (Original Research)
LS Zun, L Downey, S Brown
- 455 Simulation in Medical Student Education: Survey of Clerkship Directors in Emergency Medicine** (Brief Research Report)
C Heitz, RT Eyck, M Smith, M Fitch
- 461 Simulation in Medical School Education: Review for Emergency Medicine** (Review)
B Chakravarthy, E ter Haar, SS Bhat, CE McCoy, TK Denmark, S Lotfipour

ULTRASOUND

- 467 Comparison of Metallic Foreign-Body Removal between Dynamic Ultrasound and Static Radiography in a Pigs’ Feet Model** (Original Research)
WC Manson, JG Ryan, H Ladner, S Gupta

Policies for peer review, conflicts of interest, human and animal subjects protections and author instructions can be found online at www.westjem.org.

Western Journal of Emergency Medicine

Table of Contents,

continued

- 472 **Implications and Approach to Incidental Findings in Live Ultrasound Models**
(Brief Research Report)
JC Fox, AG Richardson, S Lopez, M Solley, S Lotfipour
- 475 **Ultrasound-Guided Peripheral Intravenous Access in the Emergency Department: Patient-Centered Survey** (Brief Research Report)
E Schoenfeld, H Shokoohi, K Boniface
- 478 **Incidental Identification of Right Atrial Mass Using Bedside Ultrasound: Cardiac Angiosarcoma**
(Case Report)
A Pourmand, K Boniface
- 481 **Bedside Ultrasound Diagnosis of Acalculous Cholecystitis from Epstein-Barr Virus**
(Case Report)
A Nagdev, J Ward

GERIATRICS

- 484 **Assessment of a Chief Complaint–Based Curriculum for Resident Education in Geriatric Emergency Medicine** (Original Research)
MC Wadman, WL Lyons, LH Hoffman, RL Muelleman
- 489 **Physician and Nurse Acceptance of Technicians to Screen for Geriatric Syndromes in the Emergency Department** (Original Research)
CR Carpenter, RT Griffey, S Stark, CM Coopersmith, BF Gage

TRAUMA

- 496 **Blunt Abdominal Trauma Patients Are at Very Low Risk for Intra-Abdominal Injury after Emergency Department Observation** (Original Research)
JL Kendall, AM Kestler, KT Whitaker, M-M Adkisson, JS Haukoos

Online Manuscripts

(Full text manuscripts available open access at http://escholarship.org/uc/uciem_westjem)

CLINICAL PRACTICE

- 505 **Oral and Tympanic Membrane Temperatures Are Inaccurate to Identify Fever in Emergency Department Adults** (Original Research)
BJ Barnett, S Nunberg, J Tai, ML Lesser, V Fridman, P Nichols, R Powell, R Silverman
- 512 **Food Protein-Induced Enterocolitis Syndrome as a Cause for Infant Hypotension** (Case Report)
RW Coates, KR Weaver, R Lloyd, N Ceccacci, MR Greenberg
- 515 **Torsion of Undescended Testis in a 14-Month-Old Child Refusing to Bear Weight** (Case Report)
RM Knight, PJ Cuenca

Policies for peer review, conflicts of interest, human and animal subjects protections and author instructions can be found online at www.westjem.org.

Western Journal of Emergency Medicine

Table of Contents,

continued

- 520 **Os Odontoideum: Rare Cervical Lesion** (Case Report)
KA Robson
- 523 **A Rare Isolated Trapezoid Fracture** (Images in Emergency Medicine)
N Afifi, JJ Lu
- 525 **Unusual Cause of Chest Pain on Radiograph** (Images in Emergency Medicine)
M Gallitelli, P De Chirico
- 526 **Continuous Diaphragm Sign** (Images in Emergency Medicine)
ER Schmitt, MD Burg
- 528 **Radiographic Evidence of Osteomyelitis** (Images in Emergency Medicine)
NT Desouza, P Govindarajan

EDUCATION

- 530 **In-Training Practice Patterns of Combined Emergency Medicine/Internal Medicine Residents, 2003–2007** (Original Research)
CS Kessler, AA Gonzalez, LA Stallings, TA Templeman
- 537 **Feedback in the Emergency Medicine Clerkship** (Review)
AW Bernard, NE Kman, S Khandelwal
- 543 **Advanced Topics in Emergency Medicine: Curriculum Development and Initial Evaluation** (Review)
NE Kman, AW Bernard, DR Martin, D Bahner, D Gorgas, R Nagel, S Khandelwal

DERMATOLOGY

- 551 **Cutaneous Conditions Leading to Dermatology Consultations in the Emergency Department** (Original Research)
AR Jack, AA Spence, BJ Nichols, S Chong, DT Williams, SP Swadron, DH Peng
- 556 **Erythema Gydatum Repens: A Rare Paraneoplastic Rash** (Case Report)
M Gore, ME Winters
- 559 **Drug Rash with Eosinophilia and Systemic Symptoms: Two Emergency Department Cases** (Case Report)
A Tsyulnik, A Landman
- 563 **A Desert Rash** (Images in Emergency Medicine)
BE Bledsoe, M Loptien, RP Berkeley

CARDIOLOGY

- 565 **Pacemaker Limitation of Tachycardia in Hypovolemic Shock** (Case Report)
N Sparacino, M Geninatti, G Moore

Policies for peer review, conflicts of interest, human and animal subjects protections and author instructions can be found online at www.westjem.org.

Western Journal of Emergency Medicine

Table of Contents,

continued

567 Cardiac Arrest from Postpartum Spontaneous Coronary Artery Dissection (Case Report)
MT Pillow, NA Nguyen, D Kuo

571 Acute Aortic Dissection in Third Trimester Pregnancy without Risk Factors (Case Report)
L Kinney-Ham, HB Nguyen, R Steele, EL Walters

TRAUMA

575 Pylephlebitis: An Uncommon Complication of Intra-Abdominal Infection
(Images in Emergency Medicine)
T Hagopian, F Zuniga, SR Surani

577 Fracture Dislocation C6 to C7: Importance of Adequate Radiographs
(Images in Emergency Medicine)
E Muñoz-Mahamud, A Combalia

579 Pericardial Cyst: Unexpected Finding on a Chest Radiograph (Images in Emergency Medicine)
ER Schmitt, MD Burg

581 Severe Open Ankle Sprain (Images in Emergency Medicine)
BA Sinnott, J Strote

Policies for peer review, conflicts of interest, human and animal subjects protections and author instructions can be found online at www.westjem.org.