

Prognostic Value of Emergency Physician Performed Echocardiography in Patients with Acute Pulmonary Thromboembolism

Maurizio Zanobetti, MD
Cristiano Converti, MD
Alberto Conti, MD
Gabriele Viviani, MD
Elisa Guerrini, MD
Vanessa Boni, MD
Sonia Vicidomini, MD
Claudio Poggioni, MD
Aurelia Guzzo, MD
Alessandro Coppa, MD
Sofia Bigiarini, MD
Francesca Innocenti, MD
Riccardo Pini, MD

Department of Critical Care Medicine and Surgery, University of Florence, Florence, Italy

Supervising Section Editor: Michael Burg, MD

Submission history: Submitted May 26, 2012; Revision received March 4, 2013; Accepted April 5, 2013

Full text available through open access at http://escholarship.org/uc/uciem_westjem

DOI: 10.5811/westjem.2013.4.12690

Introduction: Pulmonary embolism (PE) is a life-threatening illness with high morbidity and mortality. Echocardiography (ECG) plays an important role in the early identification of right ventricular (RV) dysfunction, making it a helpful tool in identifying hemodynamically stable patients affected by PE with a higher mortality risk. The purpose of this study was to evaluate if one or more ECG indexes could predict a short-term evolution towards RV dysfunction.

Methods: We selected all patients consecutively admitted to the Careggi Hospital Emergency Department with the clinical suspicion of PE, confirmed by computed tomography angiography prior to enrollment. Subsequently, properly trained emergency physicians acquired a complete ECG to measure RV morphological and functional indices. For each patient, we recorded if he or she received a fibrinolytic treatment, a surgical embolectomy or heparin therapy during the emergency department (ED) stay. Then, every patient was re-evaluated with ECG, by the same physician, after 1 week in our intensive observation unit and 1 month as outpatient in our ED regional referral center for PE.

Results: From 2002 to 2007, 120 consecutive patients affected by PE were evaluated by echocardiography at the Careggi Hospital ED. Nine patients (8%) were treated with thrombolytic therapy. Six died within 1 week and 4 abandoned the study, while the remaining 110 survived and were re-evaluated by ECG after 1 week and 1 month. The majority of the echocardiographic RV indexes improve mostly in the first 7 days: Acceleration Time (AT) from 78 ± 14 ms to 117 ± 14 ms ($p<0.001$), Diameter of Inferior Vena Cava (DIVC) from 25 ± 6 mm to 19 ± 5 mm ($p<0.001$), Tricuspid Annular Plane Systolic Excursion (TAPSE) from 16 ± 6 mm to 20 ± 6 mm ($p<0.001$). Pulmonary Artery Systolic Pressure (PASP) showed a remarkable decrease from 59 ± 26 mmHg to 37 ± 9 mmHg, ($p<0.001$). The measurements of the transverse diameters of both ventricles and the respective ratio showed a progressive normalization with a reduction of RV diameter, an increase of Left Ventricular (LV) diameter and a decrease of RV/LV ratio over time. To evaluate the RV function, the study population was divided into 3 groups based on the TAPSE and PASP mean values at the admission: Group 1 (68 patients) (TAPSE+/PASP-), Group 2 (12 patients) (TAPSE-/PASP-), and Group 3 (30 patients) (TAPSE-/PASP+). Greater values of AT, minor RV diameter, greater LV diameter and a lesser RV/LV ratio were associated with a short-term improvement of TAPSE in the Group 2. Instead, in Group 3 the only parameter associated with short-term improvement of TAPSE and PASP was the treatment with thrombolytic therapy ($p<0.0001$).

Conclusion: Greater values of AT, minor RV diameter, greater LV diameter and a lesser RV/LV ratio were associated with a short-term improvement of TAPSE-/PASP- values. Patients with evidence of RV dysfunction (TAPSE-/PASP+), may benefit from thrombolytic therapy to improve a short-term RV function. After 1 month, also a decreased DIVC predicted improved RV function. [West J Emerg Med. 2013;14(5):509–517.]

INTRODUCTION

Acute pulmonary embolism (PE) is defined as a partial or complete occlusion of the pulmonary artery branches; together with deep vein thrombosis it is a possible manifestation of the same disease: venous thromboembolism.¹ Clinical features of PE can range from a totally silent presentation to sudden dyspnea and tachypnea, associated with tachycardia, chest pain, hemoptysis or syncope. Those signs are neither specific nor sensitive, because of a wide spectrum of possible differential diagnoses, including coronary artery disease, pneumonia, congestive heart failure, pericarditis, pleurisy and primary pulmonary hypertension.^{1,2}

PE is associated with high morbidity and mortality, especially when associated with signs of right ventricular (RV) dysfunction.²⁻⁴ Patients can be prognostically stratified into 3 risk classes: high-risk PE with a short-term mortality >15% including hemodynamically unstable patients, intermediate-risk PE according to the identification of either RV dysfunction or blood markers of myocardial injury, and low-risk PE. Echocardiography (ECG) represents a very important source of prognostic information in PE, as it can recognize many signs of RV dysfunction and is therefore helpful to assign the patient to low- or intermediate-risk classes.²

Many studies have analyzed 1 or more ECG indices of RV dysfunction in relation to short-or long-term patient survival,^{3,5-16} but none assess whether 1 or more of these ECG indices could predict short-term changes of RV dysfunction or pulmonary hypertension in patients with PE. Thus, the aim of our study was to identify 1 or more ECG indices of RV anatomy and function predictors of short-term RV dysfunction in patients with PE.

METHODS

The study, which is consistent with the principles of the Declaration of Helsinki on clinical research involving human subjects, was approved by an Institutional Review Board.

We enrolled all patients consecutively admitted to the Careggi Hospital Emergency Department (ED) with current and past history, clinical symptoms, and pretest probability suggestive of PE confirmed by computed tomography angiography in this study.

Subsequently, each patient underwent an ECG to measure several morphological and functional RV indices.

Age, heart rate (HR), respiratory rate (RR), systolic blood pressure (SBP) and diastolic blood pressure (DBP) of all patients were obtained on admission to the ED; if a patient had a shock index (defined as heart rate divided by systolic blood pressure),¹⁷ >1 he or she was considered affected by high-risk PE.

All patients had a transthoracic ECG performed using standard views (parasternal long-axis view, parasternal short-axis view, apical four-chamber view and subcostal long-axis view) with M-Mode, B-Mode, Continuous-Wave Doppler, Pulsed-Wave Doppler and Color-Doppler techniques.

We acquired the images with an Acuson Sequoia 512

system (Siemens AG, Erlangen, Germany) equipped with a sectorial transducer with frequencies between 2,5 and 3,5 MHz. Each ECG was executed and interpreted by emergency physicians (EP). All EPs attended an initial training during an introductory course of 24 hours covering the core applications with practical hands-on sessions, and subsequent detailed courses covering single applications (vascular, cardiac and chest ultrasonography lasting 8 hours for each area). Then they performed, under a tutor's supervision, 250 ultrasonographic exams of each kind before being certified to perform ultrasonography.

We measured right and left ventricular dimensions following the American Society of Echocardiography guidelines.¹⁸⁻²⁰ M-mode ECG was used to evaluate the RV systolic function from long and short axis views. We detected RV long axis function by measuring the tricuspid annular plane systolic excursion (TAPSE), placing the M-mode cursor in the apical four-chamber view at the junction of the RV free wall and tricuspid annular plane and recording the longitudinal displacement of the annulus towards the apex from end-diastole to end-systole. The larger the excursion, the better was the RV systolic function, and values less than 16 mm were considered indicative of RV dysfunction.²¹ We evaluated RV short axis function from the parasternal short-axis view at the level of the aortic root. With the M-mode technique, we recorded the right ventricular outflow tract fractional shortening (RVOTFS). The dimensions were measured at end-diastole and end-systole using endocardial leading edge methodology. We calculated RV fractional shortening as the percentage fall in right ventricular outflow tract diameter in systole with respect to that in diastole.^{13,19}

We recorded the diameter of the inferior vena cava (DIVC) and its variation with inspiration expressed in percentage (%DIVC) from the subcostal long-axis view.^{19,22} The mid-cavity diameters of the right and left ventricles in end-diastole were measured from the standard parasternal long-axis, subcostal long-axis and apical four-chamber views. From these measurements, for each view we calculated the right ventricle to left ventricle ratio (RV/LV).^{19,21,23} This measure is considered an important ECG index, because a RV enlargement resulting in a RV/LV >1, can be indicative of a hemodynamically significant PE. Using the Continuous-wave Doppler technique from the parasternal short-axis view, we estimated the RV to right atrial pressure gradient, and calculated the pulmonary artery systolic pressure (PASP) with the information about the diameter and the respiratory collapse of the inferior vena cava (IVC).¹⁹

Using the Pulsed-wave Doppler technique with the sample volume positioned at the tricuspid valve in apical four-chamber view, we recorded the diastolic flow, visualizing the E and A waves of the tricuspid flow and calculating the E to A ratio (E/A) and the deceleration time of the E wave (DTE).¹⁹ Using the same technique the acceleration time of the RV (AT) was measured in the parasternal short-axis view, positioning

Table 1. Echocardiographic indices upon presentation to emergency department.

		Range	Normal values	p-value
Acceleration time of RV (ms)	77 ± 15	52-97	>120	<0.001
Diameter of the inferior vena cava (mm)	26 ± 6	17-39	<21	<0.001
RV outflow tract fractional shortening (%)	36 ± 18	5-54	>48*	<0.001
Deceleration time of the E wave (ms)	123 ± 17	92-144	<120	0.039
E to A wave ratio	0.64 ± 0.29	0.02-0.99	0.8-2.1	<0.001
Pulmonary artery systolic pressure (mmHg)	62 ± 28	36-118	<35	<0.001
Tricuspidal annular plane systolic excursion (mm)	15 ± 7	5-24	>16	NS
RV				
Apical 4-chamber view (mm)	36 ± 11	24-57	<35	NS
Parasternal long-axis view (mm)	33 ± 11	22-56	<27	<0.001
Subcostal long-axis view (mm)	35 ± 11	22-57	-	-
LV				
Apical 4-chamber view (mm)	49 ± 5	41-65	-	-
Parasternal long-axis view (mm)	49 ± 5	40-64	42-59 Male [§] 39-53 Female [§]	<0.001
Subcostal long-axis view (mm)	49 ± 5	37-66	-	-
RV/LV				
Apical 4-chamber view	0.75 ± 0.29	0.44-1.36	<0.6 [¶]	<0.001
Parasternal long-axis view	0.70 ± 0.29	0.42-1.40	-	-
Subcostal long-axis view	0.73 ± 0.29	0.42-1.36	-	-

RV, right ventricle; LV, left ventricle; RV/LV, right ventricle to left ventricle ratio

*Normal values of right ventricular outflow tract fractional shortening were obtained from the work by Lindqvist et al^{13,19} but these have not currently been validated by other studies.

[§] Normal values from 25.

[¶] Normal values from 26.

the sample volume at the pulmonary valve.^{5,19}

Furthermore, we evaluated the presence of 2 ECG signs of RV dyskinesia: the McConnell's sign (a distinct regional pattern of right ventricular dysfunction, with akinesia of the mid free wall but normal motion at the apex) and the D-shaped LV (systolic movement of the interventricular septum toward the LV).⁶

For each patient, a record was made if he or she received a fibrinolytic treatment, a surgical embolectomy or heparin therapy during the ED stay. Then every patient was re-evaluated with ECG, by the same EP, after 1 week in our Intensive Observation Unit and 1 month as outpatient in our ED regional referral center for pulmonary embolism.

Statistical analysis

Data are presented as mean ± standard deviation for continuous variables, and numbers or percentage for categorical variables. We tested differences by Student's t test or χ square test or Fisher's exact test, as appropriate. Analysis of variances and Sheffé's post-hoc test assessed differences for multiple comparisons of continuous variables. Univariate logistic regression analysis assessed the association between every ECG parameter and the 7-day survival, eventually followed by a multivariate logistic regression analysis.

To characterize RV functionality in terms of contractility and pressure developed, TAPSE and PASP were exploited. It was possible to identify 3 groups of patients using the mean values of these 2 parameters: Group 1 with TAPSE over the mean value and PASP under the mean value (TAPSE+/PASP-), Group 2 with TAPSE and PASP below the mean value (TAPSE-/PASP-), and Group 3 with TAPSE under the mean value and PASP elevated over the mean value (TAPSE-/PASP+).

A 2-tailed p value <0.05 was considered statistically significant in all calculations. We did all computations using SPSS statistical package (SPSS version 17 Inc. Chicago, IL, USA).

RESULTS

We enrolled 120 patients (44% male) who had been diagnosed with pulmonary embolism in the ED by computed tomography (CT) angiography from January 2002 to December 2007. Mean age was 73±14 years, and at the time of presentation 12 patients (10%) were in shock. The remaining 108 patients (90%) had a mean HR of 101±25 beats per minute, a RR of 23±9 breaths per minute, a SBP of 130±25 mmHg and a DBP of 77±13 mmHg.

One-hundred eleven of the 120 patients (92%) never

Table 2. Result of the comparison between the echocardiographic indices registered upon admission to the emergency department, after 1 week and after 1 month.

	1 week	1 month	ANOVA
Acceleration time of RV (ms)	117 ± 14*	119 ± 21	p<0.001
Diameter of the inferior vena cava (mm)	19 ± 5*	17 ± 3	p<0.001
RV outflow tract fractional shortening (%)	49 ± 14*	53 ± 13	p<0.001
Deceleration time of the E wave (ms)	145 ± 19*§	158 ± 16§	p<0.001
E to A wave ratio	0.93 ± 0.28*§	1.13 ± 0.28§	p<0.001
Pulmonary artery systolic pressure (mmHg)	37 ± 9* [¶]	30 ± 8 [¶]	p<0.001
Tricuspid annular plane systolic excursion (mm)	20 ± 6*	22 ± 6	p<0.001
RV			
Apical 4-chamber view (mm)	29 ± 7*	27 ± 6	p<0.001
Parasternal long-axis view (mm)	26 ± 6*	25 ± 4	p<0.001
Subcostal long-axis view (mm)	28 ± 6*	26 ± 5	p<0.001
LV			
Apical 4-chamber view (mm)	51 ± 4*	52 ± 4	p<0.001
Parasternal long-axis view (mm)	51 ± 4*	52 ± 3	p<0.001
Subcostal long-axis view (mm)	51 ± 5*	52 ± 4	p<0.001
RV/LV			
Apical 4-chamber view	0.59 ± 0.18*	0.53 ± 0.13	p<0.001
Parasternal long-axis view	0.52 ± 0.14*	0.49 ± 0.10	p<0.001
Subcostal long-axis view	0.57 ± 0.16*	0.51 ± 0.11	p<0.001

RV, right ventricle; LV, left ventricle; RV/LV, right ventricle to left ventricle ratio

* p<0.001 compared with the values at the admission with the Sheffé's post-hoc test.

§ p<0.001 compared with the Sheffé's post-hoc test.

¶ p=0.025 compared with the Sheffé's post-hoc test.

had a history of PE, while 9 (8%) had a recurrence of venous thromboembolism. Nine of the 120 patients (8%) were treated with thrombolytic therapy.

In 9 patients (8%) the ECG exam was incomplete due to inadequate visualization of the heart. Therefore, it was not possible to record the dimensions of the RV in 1 patient in parasternal long-axis view (1%) and in 9 patients (8%) in subcostal long-axis view, and the LV was impossible to evaluate in 8 patients (7%) in subcostal long-axis view.

Six patients (5%) died within a week, and all belonged to group 3 (TAPSE-/PASP+). One of these was treated with thrombolytic therapy. Two patients (2%) received a surgical embolectomy because of absolute contraindications to fibrinolysis, 1 (1%) was transferred to another hospital and 1 (1%) refused admission to the hospital; the remaining 110 patients (92%) were hospitalized and followed up with ECG after 1 week and 1 month.

The mean values of the ECG indices we evaluated were altered at ED presentation, compared to normal values presented in other studies, except for TAPSE and the mid-cavity diameter of the RV in the apical four-chamber view (Table 1).

Analyzing the development of the various ECG indices obtained from the 110 patients that were re-evaluated after

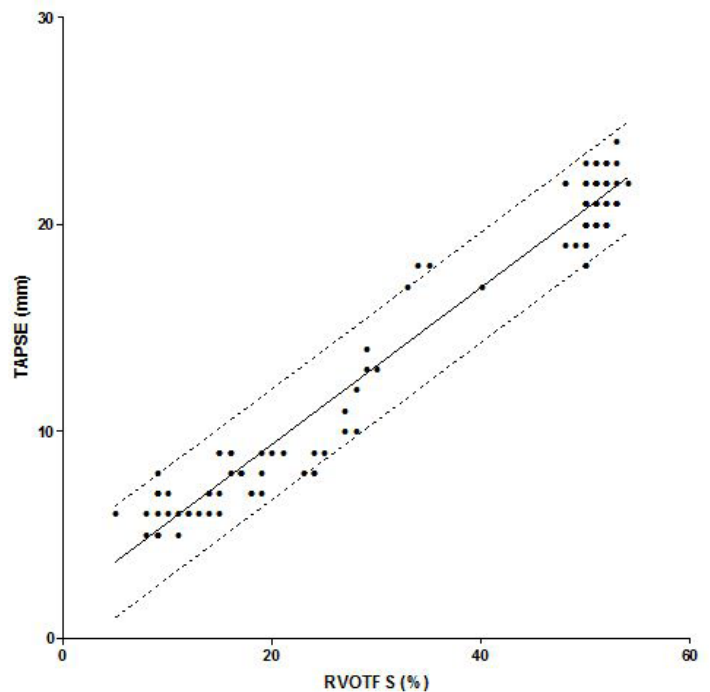


Figure 1. Correlation between right ventricular outflow tract fractional shortening (RVOTFS) and tricuspid annular plane systolic excursion (TAPSE) values of the right ventricle registered at the admission. The central continuous line indicates the regression line. The dashed lines indicates the standard error of estimates.

Table 3. Echocardiographic indices: age and vital signs in deceased and 30-day survivor subgroups.

	Dead	Survivors	p-value
Acceleration time of RV (ms)	55 ± 1	78 ± 14	<0.001
Diameter of the inferior vena cava (mm)	36 ± 2	25 ± 6	<0.001
RV outflow tract fractional shortening (%)	9 ± 2	38 ± 16	<0.001
Deceleration time of the E wave (ms)	100 ± 3	125 ± 16	<0.001
E to A wave ratio	0.25 ± 0.05	0.67 ± 0.27	<0.001
Pulmonary artery systolic pressure (mmHg)	110 ± 6	59 ± 26	<0.001
Tricuspidal annular plane systolic excursion (mm)	5 ± 1	16 ± 6	<0.001
RV			
Apical 4-chamber view (mm)	29 ± 7	27 ± 6	<0.001
Parasternal long-axis view (mm)	26 ± 6	25 ± 4	<0.001
Subcostal long-axis view (mm)	28 ± 6	26 ± 5	<0.001
LV			
Apical 4-chamber view (mm)	51 ± 4	52 ± 4	<0.001
Parasternal long-axis view (mm)	51 ± 4	52 ± 3	<0.001
Subcostal long-axis view (mm)	51 ± 5	52 ± 4	<0.001
RV/LV			
Apical 4-chamber view	0.59 ± 0.18	0.53 ± 0.13	<0.001
Parasternal long-axis view	0.52 ± 0.14	0.49 ± 0.10	<0.001
Subcostal long-axis view	0.57 ± 0.16	0.51 ± 0.11	<0.001
Age (years)	82 ± 14	73 ± 13	NS
Systolic arterial blood pressure (mmHg)	138 ± 17	129 ± 25	NS
Diastolic arterial blood pressure (mmHg)	83 ± 15	76 ± 13	NS
Heart rate (beats/min)	130 ± 12	100 ± 26	NS
Respiratory rate (breaths/min)	36 ± 7	23 ± 9	NS

RV, right ventricle; LV, left ventricle; RV/LV, right ventricle to left ventricle ratio

1 week and 1 month, we found that the majority improved primarily in the first 7 days, with further, but not statistically significant, improvements within 1 month (Table 2).

In detail, the AT improved from a mean value of 78 ± 14 ms, recorded at the first ECG done in the ED, to 117 ± 14 ms after 1 week ($p < 0.001$); after a month the improvement was minimally better (119 ± 21 ms) but not statistically significant (versus 1 week).

The dimension of the inferior vena cava associated with its collapsibility during inspiration is a very reliable parameter to estimate right atrial pressure (RAP), and accordingly central venous pressure. DIVC showed a progressive and significant decrease, starting from mean values of 25 ± 6 mm at presentation to 19 ± 5 mm after one week ($p < 0.001$), decreasing further to a mean value of 17 ± 3 mm after 1 month ($p = \text{NS}$ versus 1 week).

The RVOTFS was described by Lindqvist et al¹³ at least as reliable as TAPSE for the evaluation of RV function: according to our analysis, RVOTFS was correlated with TAPSE showing a progressive increase of the average value (38 ± 16% at presentation, 49 ± 14% after 1 week, $p < 0.001$,

and 53 ± 13% after 1 month, $p = \text{NS}$ versus 1 week), comparable to that of TAPSE (16 ± 6 mm at presentation, 20 ± 6 mm after 1 week, $p < 0.001$, and 22 ± 6 mm after 1 month, $p = \text{NS}$ versus 1 week).

The 2 parameters showed a highly significant linear correlation ($r = 0.980$; $p < 0.001$) and the standard error in the estimate of TAPSE using the RVOTFS values was ±1.34 mm. The range of TAPSE observed in our study is 5-24 mm, and using the RVOTFS to assess TAPSE, there would be a mean error of approximately ±9% (Figure 1).

The DTE and the E/A of the trans-tricuspid flow measured with Doppler technique are ECG indices of diastolic function of the right heart; these parameters significantly improved in our patients, showing an increase of the mean value of DTE from 125 ± 16 ms at the admission to 145 ± 19 ms after 1 week ($p < 0.001$), to 158 ± 16 ms after 1 month ($p = \text{NS}$ versus one week), while E/A mean value started from 0.67 ± 0.27 at the admission and increased after 7 days to 0.93 ± 0.28 ($p < 0.001$) and then to 1.13 ± 0.28 after 1 month ($p = \text{NS}$ versus 1 week).

The estimate of PASP showed a remarkable and

Table 4. Correlation according to the logistic univariate regression model of echocardiographic indices compared with the 7-day mortality, with relative *p*-value, odds ratio and confidence interval.

	<i>p</i> -value	Odds ratio	95% confidence interval
Acceleration time of RV (ms)	NS		
Diameter of the inferior vena cava (mm)	0.015	1.469	1.076-2.006
RV outflow tract fractional shortening (%)	NS		
Deceleration time of the E wave (ms)	0.018	0.860	0.758-0.974
E to A wave ratio	0.027	3x10 ⁻⁶	4x10 ⁻¹¹ -0.228
Pulmonary artery systolic pressure (mmHg)	NS		
Tricuspidal annular plane systolic excursion (mm)	NS		
RV			
Apical 4-chamber view (mm)	NS		
Parasternal long-axis view (mm)	0.023	3.593	1.189-10.859
Subcostal long-axis view (mm)	NS		
LV			
Apical 4-chamber view (mm)	0.014	0.230	0.071-0.742
Parasternal long-axis view (mm)	0.009	0.492	0.289-0.839
Subcostal long-axis view (mm)	0.012	0.685	0.509-0.921
RV/LV			
Apical 4-chamber view	NS		
Parasternal long-axis view	NS		
Subcostal long-axis view	NS		

RV, right ventricle; LV, left ventricle; RV/LV, right ventricle to left ventricle ratio; NS, not statistically significant

progressive decrease in our series: starting from a mean value of 59 ± 26 mmHg upon admission. After 7 days we saw a marked and statistically significant decrease in pressure (37 ± 9 mmHg, *p*<0.001) that continued even after 1 month (30 ± 8 mmHg, *p*=NS versus 1 week).

The measurements of the transverse diameters of both ventricles and the respective ratio in the apical 4-chamber, parasternal long-axis and subcostal long axis views all showed a progressive normalization of the mean values, which is a reduction of RV dimension, an increase of LV dimension and a RV/LV ratio that decreased over time (Table 2).

Comparing survivors with non-survivors at 1 month, we saw that all the ECG indices we studied showed differences between the 2 groups (*p*<0.001), but age and vital signs registered on admission to the ED did not show statistically significant differences (Table 3).

In the univariate logistic regression analysis the parameters that showed an association with increased mortality within 7 days were as follows: an increased DIVC, an augmented DTE, a decreased E/A, an increased RV diameter in parasternal long-axis view and a diminished LV diameter in all 3 ECG views we performed (Table 4); but when those parameters were included in a multivariate logistic regression model, none of them proved to be an independent

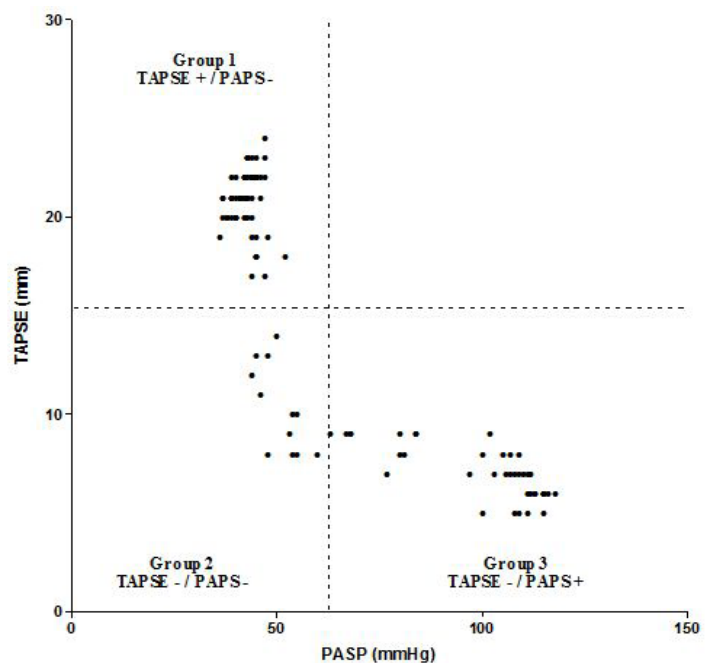


Figure 2. Distribution of patients according to tricuspid annular plane systolic excursion (TAPSE) and pulmonary artery systolic pressure (PASP) values at the admission. Dotted lines represent the mean values of TAPSE and PASP and divide the population in 3 Groups.

predictor of 7-day mortality ($p=NS$).

McConnell's sign was found in 45 patients (39%) upon admission. Six of them died within 1 week. The 75 patients without McConnell's sign survived 1 month ($p=0.003$).

All survivors with positive McConnell's sign (39) were still positive for this sign after 1 week ($p=NS$), but after 1 month McConnell's sign was detected in 21 patients ($p=0.047$).

The presence of a D-shaped LV was detectable in 55 patients (47%) upon admission and was present in 6 of the patients who died within 7 days, unlike the group of the 55 patients that did not have a D-shaped LV, who all survived one month ($p=0.01$).

Of the 49 patients with D-shaped LV that survived, 26 had this finding after 1 week ($p=0.0051$), with only 1 patient still positive after 1 month ($p<0.001$).

Of the 42 patients (36%) whose IVC was not collapsible, 6 died within 7 days, while all those whose IVC was collapsible with inspiration survived ($p=0.002$).

Of the 36 survivors with non-collapsible IVC, only 1 patient had this sign ($p<0.001$) after 1 week and 1 month, while the others reverted to normal ($p=NS$).

Therefore, the presence of McConnell's sign, a D-shaped LV, or evidence of a non-collapsible IVC with inspiration showed a correlation with a higher mortality. However, performing further regression curve analysis, this relationship was not statistically significant ($p=NS$).

To evaluate right heart function, we divided the population of our study into 3 groups based on the TAPSE and PASP values: at the admission in the ED, 68 patients formed Group 1 (TAPSE+/PASP-), 12 patients formed Group 2 (TAPSE-/PASP-) and the remaining 30 patients formed Group 3 (TAPSE-/PASP+) (Figure 2). All patients in Group 1 remained in this group after 1 week and 1 month, not showing a deterioration in right heart function. After 1 week, 10 of 12 patients (83%) in Group 2 showed an improvement of right ventricular contractility (TAPSE+) moving to Group 1. The remaining 2 patients (17%) showed no improvement even after 1 month, remaining in the initial group. In Group 3, the majority (22 out of 30, 73%) moved to Group 2 due to a reduction of pulmonary hypertension (PASP-) not associated with a significant improvement of the systolic function of the RV, while the remaining 8 patients (27%) moved directly to Group 1 due to both an improvement of RV systolic function and reduction of pulmonary hypertension (TAPSE+/PASP-). After 1 month, 5 out of 22 patients that moved from Group 3 to Group 2 showed a further improvement, shifting to Group 1. The following findings were all associated with a short-term improvement of TAPSE and PASP in this subgroup of patients: greater values of AT, a smaller RV diameter, a greater LV diameter in parasternal and subcostal-long axis views and a lower RV/LV ratio in apical four-chamber and subcostal long-axis views.

In Group 3 the only parameter related to 7-days

improvement of RV function was the receipt of thrombolytic therapy. Indeed among this group of 30 patients, 22 (73%) did not receive thrombolytics, and improved to Group 2 status due to reduction of pulmonary hypertension (PASP-) but not a significant improvement in systolic function of the RV. The remaining 8 (27%) patients who were treated with thrombolysis, improved to a greater degree and moved directly to Group 1 due to both improvement of RV systolic function (TAPSE+) and reduction of pulmonary hypertension (PASP-). This difference in degree of improvement between the 22 patients without thrombolytics and the 6 with, was statistically significant ($p<0.0001$) (Fisher's Exact Test). Furthermore, we note that 6 of the 8 patients thrombolysed, had intermediate-risk PE, while 2 were in shock, indicating that thrombolytic therapy may be of benefit not only for patients in extremis. Finally in Group 3 a decreased DIVC after 1 month was predictive of an improvement in RV function.

DISCUSSION

Our study investigated whether 1 or more ECG indexes could predict a short-term evolution towards RV dysfunction in patients affected by PE. Accordingly, the study was not aimed at evaluating the diagnostic ECG indices suggestive of pulmonary thromboembolism that were already extensively evidenced in the medical literature. Being able to predict short-term evolution towards RV dysfunction is important for the EP, to tailor therapy in the first hours after diagnosis according to the hemodynamic profile. We examined a consecutive group of 120 patients with PE on CT angiography, without regard to severity determined purely on clinical presentation.

Mortality rate in our population (5%) was similar to that of other studies.^{3,4,24} In those who survived (and excluding those not re-evaluable by ECG) the evolution after 1 week and 1 month of every ECG index was recorded. Every index showed a more or less rapid back-to-normal trend, but in some patients this trend was much slower than in others.

We used 2 ECG parameters studied extensively TAPSE and PASP to identify patients with a worse right heart dysfunction among those with the same clinical severity.

This way, we managed to verify an improvement or not of the right heart dysfunction after 1 week and 1 month, and so a favorable outcome or not, as reported in literature.¹⁶

As a matter of fact, in the group in which TAPSE and PASP were under the mean values, a higher AT, lower diameters of the RV, greater diameters of the LV, and a lower RV/LV ratio were all related to the improvement of the RV dysfunction after only 1 week from the episode of PE.

In the group 3, TAPSE-/PASP+, we were able to predict considerable improvement of RV dysfunction after 7 days, only if the patients had been treated with thrombolysis compared to those treated only with heparin. Furthermore, since the majority of patients who received

thrombolytic therapy (6 out of 8) belonged to the category at intermediate prognostic risk of pulmonary embolism, we can reasonably state that not only patients with high-risk PE (hemodynamically unstable patients) (2 out of 8) but also patients with an intermediate-risk PE showing an impairment of the RV function (reduced TAPSE and elevated PAPS) may benefit from thrombolytic therapy², after the exclusion of bleeding risk factors. This is very important for the ED physician approach to PE. These results therefore allow for the chance to improve the clinical status of a patient with PE based solely on ECG parameters recorded at the time of presentation in the ED.

Regarding DIVC, our study showed that this index remained higher than normal after 1 month, documenting the persistence of right heart dysfunction.

Moreover, we investigated the association between TAPSE and RVOTs, as described by Lindqvist et al.¹³ In those authors' opinion, RVOTs is strictly related to TAPSE and in patients with PE it is highly indicative of RV dysfunction.

In our study, we confirmed the existence of a direct correlation between those 2 parameters, but TAPSE has a standard error of estimates of about ± 1.34 mm for constant values of RVOTs. This means that for every value of RVOTs, TAPSE would have a CI of ± 2.6 mm in a population in which TAPSE ranges from 5 to 24. This information, along with the absence in the literature of a reference value for normal population, suggests that further study is needed for a better definition of the relationship between TAPSE and RVOTs.

This study is the first analysis on the prognostic indices for PE detected by ECG in the emergency medicine literature.

LIMITATIONS

The most important limitation of our study is that we analyzed a highly select population in which the diagnosis of PE was already done, although the first ECG was performed in the ED soon after the CT angiogram.

CONCLUSION

ECG represents an invaluable instrument for the definition of prognosis of patients with PE. Even though an index or ECG sign that is more specific than another does not exist, each one supports the classification as an "intermediate-risk patient," and only the absence of any sign of RV dysfunction predicts a good short-term prognosis.

In intermediate-risk patients AT, RV diameter in all views, LV diameter in parasternal long-axis and subcostal long-axis views, and the RV/LV ratio in apical 4-chamber and subcostal long-axis views could also be investigated to obtain information about diagnosis and rate of improvement in right heart dysfunction.

Moreover, although it is also recognized that massive acute pulmonary embolism causing a hemodynamic instability is the clearest indication for thrombolytic agents, thrombolysis is probably useful in some patients with hemodynamic

stability. This study attempts to identify how many and which patients are the best candidates. We found that those patients with low bleeding risk affected by intermediate-risk PE in which TAPSE is depressed and PASP is elevated could benefit from a thrombolytic therapy. This would result in a short-term improvement in RV function compared to those patients treated with heparin alone. Finally, patients in whom DIVC remains elevated after 1 month will maintain the RV dysfunction, with the long-term risks related to this condition. Further investigations, with a larger sample size will be needed to confirm these data.

Address for Correspondence: Maurizio Zanobetti, MD, SOD Osservazione Breve Intensiva, Azienda Ospedaliero-Universitaria Careggi, Largo Brambilla, 350134 Firenze, Italy. Email: zanomau@libero.it.

Conflicts of Interest: By the WestJEM article submission agreement, all authors are required to disclose all affiliations, funding sources and financial or management relationships that could be perceived as potential sources of bias. The authors disclosed none.

REFERENCES

1. Tapson VF. Acute pulmonary embolism. *N Engl J Med* 2008;358:1037-1052
2. Torbicki A, Perrier A, Konstantinides S, et al. Guidelines on the diagnosis and management of acute pulmonary embolism: the Task Force for the Diagnosis and Management of Acute Pulmonary Embolism of the European Society of Cardiology (ESC). *Eur Heart J* 2008;29:2276-2315
3. Grifoni S, Olivetto I, Cecchini P, et al. Short-term clinical outcome of patients with acute pulmonary embolism, normal blood pressure, and echocardiographic right ventricular dysfunction. *Circulation* 2000;101:2817-2822
4. Kucher N, Rossi E, De RM, et al. Prognostic role of echocardiography among patients with acute pulmonary embolism and a systolic arterial pressure of 90 mm Hg or higher. *Arch Intern Med* 2005;165:1777-1781
5. Kurzyna M, Torbicki A, Pruszczyk P, et al. Disturbed right ventricular ejection pattern as a new Doppler echocardiographic sign of acute pulmonary embolism. *Am J Cardiol* 2002;90:507-511
6. McConnell MV, Solomon SD, Rayan ME, et al. Regional right ventricular dysfunction detected by echocardiography in acute pulmonary embolism. *Am J Cardiol* 1996;78:469-473
7. Toosi MS, Merlino JD, Leeper KV. Prognostic value of the shock index along with transthoracic echocardiography in risk stratification of patients with acute pulmonary embolism. *Am J Cardiol* 2008;101:700-705
8. Kjaergaard J, Schaadt BK, Lund JO, et al. Quantitative measures of

- right ventricular dysfunction by echocardiography in the diagnosis of acute nonmassive pulmonary embolism. *J Am Soc Echocardiogr* 2006;19:1264-1271
9. Kjaergaard J, Schaadt BK, Lund JO, et al. Prognostic importance of quantitative echocardiographic evaluation in patients suspected of first non-massive pulmonary embolism. *Eur J Echocardiogr* 2009;10:89-95
 10. Kjaergaard J, Schaadt BK, Lund JO, et al. Quantification of right ventricular function in acute pulmonary embolism: relation to extent of pulmonary perfusion defects. *Eur J Echocardiogr* 2008;9:641-645
 11. Chung T, Emmett L, Mansberg R, et al. Natural history of right ventricular dysfunction after acute pulmonary embolism. *J Am Soc Echocardiogr* 2007;20:885-894
 12. Rydman R, Soderberg M, Larsen F, et al. Echocardiographic evaluation of right ventricular function in patients with acute pulmonary embolism: a study using tricuspid annular motion. *Echocardiography* 2010;27:286-293
 13. Lindqvist P, Henein M, Kazzam E. Right ventricular outflow-tract fractional shortening: an applicable measure of right ventricular systolic function. *Eur J Echocardiogr* 2003;4:29-35
 14. Nakamura K, Miyahara Y, Ikeda S, et al. Assessment of right ventricular diastolic function by pulsed Doppler echocardiography in chronic pulmonary disease and pulmonary thromboembolism. *Respiration* 1995;62:237-243
 15. Milan A, Magnino C, Veglio F. Echocardiographic indexes for the non-invasive evaluation of pulmonary hemodynamics. *J Am Soc Echocardiogr* 2010;23:225-239
 16. Grifoni S, Vanni S, Magazzini S, et al. Association of persistent right ventricular dysfunction at hospital discharge after acute pulmonary embolism with recurrent thromboembolic events. *Arch Intern Med* 2006;166:2151-2156
 17. Kucher N, Luder CM, Dornhofer T, et al. Novel management strategy for patients with suspected pulmonary embolism. *Eur Heart J* 2003;24:366-376
 18. Sahn DJ, DeMaria A, Kisslo J, et al. Recommendations regarding quantitation in M-mode echocardiography: results of a survey of echocardiographic measurements. *Circulation* 1978;58:1072-1083
 19. Rudski LG, Lai WW, Afilalo J, et al. Guidelines for the echocardiographic assessment of the right heart in adults: a report from the American Society of Echocardiography endorsed by the European Association of Echocardiography, a registered branch of the European Society of Cardiology, and the Canadian Society of Echocardiography. *J Am Soc Echocardiogr* 2010;23:685-713
 20. Shiller NB, Shah PM, Crawford MH, et al. Recommendation for quantitation of left ventricle by two dimensional echocardiography. *J Am Soc Echocardiogr* 1989;2:358-367
 21. Horton KD, Meece RW, Hill JC. Assessment of the right ventricle by echocardiography: a primer for cardiac sonographers. *J Am Soc Echocardiogr* 2009;22:776-792
 22. Ommen SR, Nishimura RA, Hurrell DG, et al. Assessment of right atrial pressure with 2-dimensional and Doppler echocardiography: a simultaneous catheterization and echocardiographic study. *Mayo Clin Proc* 2000;75:24-29
 23. Lai WW, Gauvreau K, Rivera ES, et al. Accuracy of guideline recommendations for two-dimensional quantification of the right ventricle by echocardiography. *Int J Cardiovasc Imaging* 2008;24:691-698
 24. ten WM, Sohne M, Quak E, et al. Prognostic value of echocardiographically assessed right ventricular dysfunction in patients with pulmonary embolism. *Arch Intern Med* 2004;164:1685-1689
 25. Lang RM, Bierig M, Devereux RB, et al. Recommendations for chamber quantification: a report from the American Society of Echocardiography's Guidelines and Standards Committee and the Chamber Quantification Writing Group, developed in conjunction with the European Association of Echocardiography, a branch of the European Society of Cardiology. *J Am Soc Echocardiogr* 2005;18:1440-1463
 26. Sarti A. Ecocardiografia per l'intensivista. 1st[7], 73-77. 2009. Springer. Ref Type: Edited Book