

## Man with Altered Mentation after Trauma

Landon A. Jones, MD\*  
Matthew J. Sarsfield, MD†

\*Department of Emergency Medicine, Cox South Emergency and Trauma Center, Springfield, Missouri

†Department of Emergency Medicine, State University of New York Upstate Medical University, Syracuse, New York

Supervising Section Editor: Sean O. Henderson, MD

Submission history: Submitted November 18, 2013; Revision received December 4, 2013; Accepted January 6, 2014

Electronically published April 4, 2014

Full text available through open access at [http://escholarship.org/uc/uciem\\_westjem](http://escholarship.org/uc/uciem_westjem)

DOI: 10.5811/westjem.2014.1.20487

[West J Emerg Med. 2014;15(4):352–353.]

A 37 year-old male presented after an altercation in which he was dragged by a vehicle. The patient was intoxicated and asking repetitive questions. He demonstrated significant facial trauma—including frank bloody discharge from both ears and dental trauma. His vital signs were as follows: Temperature 36.8 C; Blood pressure: 125/88; Heart rate: 90; Respiratory rate: 24; O<sub>2</sub> sat: 100% room air. His portable chest x-ray can be seen below (Figure 1).

Secondary to his mechanism, intoxication, and chest radiograph results, he was sent for computed tomography (CT) imaging. Immediately post CT, his imaging was reviewed (Figure 2). Shortly thereafter, the patient's altered mentation worsened and he acutely decompensated.

### DIAGNOSIS

*Iatrogenic air embolism.* Iatrogenic air embolism is a rare side-effect of invasive and surgical procedures. While rare, retrospective studies demonstrate mortality up to 23% and recent prospective literature demonstrates a 1-year mortality of 21%. Morbidity is higher.<sup>1-5</sup> Iatrogenic air emboli can be either arterial or venous. Arterial gas emboli (AGE) can manifest as chest pain, transient ischemic attack, stroke, or shock.<sup>3,5-7</sup> While most are asymptomatic, venous gas emboli (VGE) more commonly present as shortness of breath.<sup>5,6</sup>

It is important, though, to recognize that VGE can readily convert to AGE via right-to-left shunting mechanisms such as pulmonary arterial-venous malformations and patent foramen ovale (PFO). A PFO is present in approximately 26-39% of the general population.<sup>8-11</sup> Additionally, it is important to remember that iatrogenic air emboli can occur secondary to procedures that we often consider routine in the emergency department, i.e., central line placement or—like our patient—CT with intravenous contrast.

In our case the patient acutely decompensated, was intubated, and received hyperbaric oxygen therapy. After

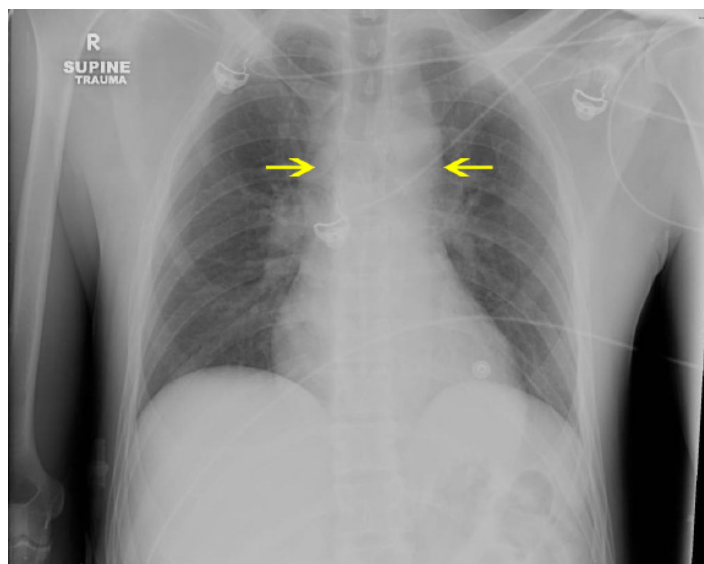


Figure 1. Chest radiograph demonstrating a widened upper mediastinum.

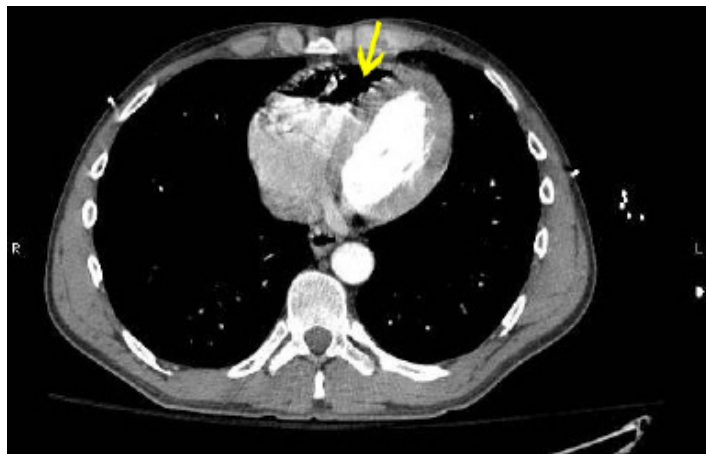


Figure 2. Computed tomography of the thorax with intravenous contrast demonstrates a large right ventricular air embolus.

hyperbarics, the patient's status improved and he was extubated in the intensive care unit and later discharged without complications.

---

*Address for Correspondence:* Landon Jones, MD. 1950 S. Scenic Ave., Apt F108, Springfield, MO 65807. Email: Landon.JonesEM@gmail.com.

---

*Conflicts of Interest:* By the WestJEM article submission agreement, all authors are required to disclose all affiliations, funding sources and financial or management relationships that could be perceived as potential sources of bias. The authors disclosed none.

## REFERENCES

1. Murphy BP, Harford FJ, Cramer FS. Cerebral air embolism resulting from invasive medical procedures: treatment with hyperbaric oxygen. *Ann Surg.* 1985 Feb; 201(2):242-245.
2. Massey EW, Moon RE, Shelton D, et al. Hyperbaric oxygen therapy of iatrogenic air embolism. *J Hyperbaric Med.* 1990; 5(1):15-21.
3. Blanc P, Boussuges A, Henriette K, et al. Iatrogenic cerebral air embolism: importance of an early hyperbaric oxygenation. *Intensive Care Med.* 2002 May; 28(5):559-563.
4. Bessereau J, Genotelle N, Chabbaut C, et al. Long-term outcome of iatrogenic gas embolism. *Intensive Care Med.* 2010;36(7):1180-1187.
5. Scruggs JE, Joffe A, Wood KE. Paradoxical air embolism successfully treated with hyperbaric oxygen. *J Intensive Care Med.* 2008 May-Jun; 23(3):204-209.
6. Jorgensen TB, Sorensen AM, Jansen EC. Iatrogenic systemic air embolism treated with hyperbaric oxygen therapy. *Acta Anaesthesiol Scand.* 2008 Apr; 52(4):566-568.
7. le SR, Rozans MH, Szerlip HM. Air embolism after intravenous injection of contrast material. *South Med J.* 1999 Sep; 92(9):930-933.
8. Kerut EK, Norfleet WT, Plotnick GD, et al. Patent foramen ovale: a review of associated conditions and the impact of physiological size. *J Am Coll Cardiol.* 2001 Sep; 38(3):613-623.
9. Hara H, Virmani R, Ladich E, et al. Patent foramen ovale: current pathology, pathophysiology, and clinical status. *J Am Coll Cardiol.* 2005 Nov 1; 46(9):1768-1776.
10. Kerr AJ, Buck T, Chia K, et al. Transmitral doppler: a new transthoracic contrast method for patent foramen ovale detection and quantification. *J Am Coll Cardiol.* 2000 Nov 15; 36(6):1959-1966.
11. Hagen PT, Scholz DG, Edwards WD. Incidence and size of patent foramen ovale during the first 10 decades of life: an autopsy study of 965 normal hearts. *Mayo Clin Proc.* Jan 1984; 59(1):17-20.