

Incidental Finding in a Headache Patient: Intracranial Lipoma

Ozlem Bilir, MD*
Ozcan Yavasi, MD*
Gokhan Ersunan, MD*
Kamil Kayayurt, MD*
Tugba Durakoglulugil, MD†

* Recep Tayyip Erdogan University, Department of Emergency Medicine, Rize, Turkey
† Recep Tayyip Erdogan University, Department of Radiology, Rize, Turkey

Supervising Section Editor: Sean O. Henderson, MD

Submission history: Submitted January 18, 2014; Revision received February 13, 2014; Accepted April 2, 2014

Electronically published May 23, 2014

Full text available through open access at http://escholarship.org/uc/uciem_westjem

DOI: 10.5811/westjem.2014.4.21298

[West J Emerg Med. 2014;15(4):361–362.]

A 60 year old female, with a history of atrial fibrillation who was on warfarin therapy, presented to our emergency department with chief complaint of the most severe headache that she ever had. Her vital signs, systemic and neurological examinations were normal. She had emergency computed tomography (CT) of the brain with suspicion of intracranial hemorrhage that revealed a lesion in fat density in the lateral ventricle and interhemispheric fissure (Figure a). Her international normalized ratio was 3,2. She underwent cranial magnetic resonance imaging (MRI) that revealed a hyperintense lesion in T1 and T2 sequences in the lateral ventricles, pericallosal area and interhemispheric fissure that did not show contrast enhancement (Figure b and c). After the symptomatic relief by analgesics she was discharged from the emergency department for out-patient follow-up.

Intracranial lipomas are rare and benign congenital malformations accounting for 0,1% to 0,46% of all intracranial tumors.¹ Since half of all cases are asymptomatic, they are usually

an incidental finding during neuroimaging studies. Headache is the most common symptom in adults if it becomes symptomatic.²

The deep interhemispheric fissure, especially the corpus callosum, is the most common localization of intracranial lipomas.¹ Intracranial lipomas are often associated with other malformations of the central nervous system, such as callosal agenesis or hypogenesis, spina bifida or a cranium bifidum.^{1,3}

Noncontrast cranial CT and brain MRI allow definitive diagnosis. The appearance of the corpus callosum lipoma on the cranial CT scan is quite typical, with the low attenuation seen only in adipose tissue, which ranges from -40 to -100 Hounsfield units.^{4,5} In the brain MRI the lesion presents characteristics of fatty tissue, with a hyperintense signal in both T1 and T2-weighted studies.⁶

Most lipomas are treated conservatively and rarely requires neurosurgical treatment because of their benign nature.¹ Our patient did not have any accompanying lesion and was discharged to follow-up as an out-patient.

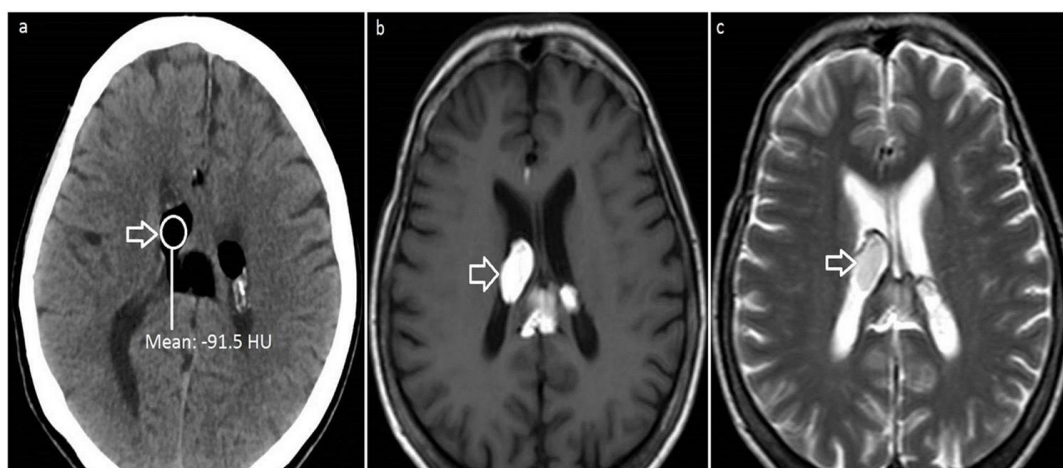


Figure. Image (a) shows cranial computed tomography. There is a homogenously hypodense lesion measuring 33 mm x 30 mm in the lateral and third ventricles with about -101 to -110 Hounsfield unit. Image (b) and (c) show magnetic resonance imaging with hyperintense mass lesion in lateral ventricle (T1-weighted and T2-weighted images, respectively).

Address for Correspondence: Ozcan Yavasi, MD, Recep Tayyip Erdogan University, Rize Research and Training Hospital, Department of Emergency Medicine, 53020 Rize, Turkey. Email: ozcanyavasi@yahoo.com.tr.

Conflicts of Interest: By the WestJEM article submission agreement, all authors are required to disclose all affiliations, funding sources and financial or management relationships that could be perceived as potential sources of bias. The authors disclosed none.

REFERENCES

1. Truwit CL, Barkovich AJ. Pathogenesis of intracranial lipoma: an MR study in 42 patients. *AJR Am J Roentgenol.* 1990;155:855-64.
2. Yilmaz N, Unal O, Kiyimaz N, et al. Intracranial lipomas-a clinical study. *Clin Neurol Neurosurg.* 2006;108(4):363-8.
3. Gerber SS, Plotkin R. Lipoma of the corpus callosum. Case report. *J Neurosurg.* 1982;57:281-5.
4. Jiménez Caballero PE. Interhemispheric lipoma associated with agenesis of the corpus callosum. *Neurologia.* 2012;27(8):515.
5. Kikuchi K, Kowada M, Watanabe K. Computed tomography of an intracranial lipoma confined in the suprasellar cistern. *Comput Med Imaging Graph.* 1994;18:187-92.
6. Hua CL. Agenesis and lipoma of the corpus callosum: MR findings. *AJR Am J Roentgenol.* 1990;154(6):1348.