

## Handlebar Trauma Causing Small Bowel Hernia with Jejunal Perforation

Serpil Yaylaci, MD\*  
 Hasan Ercelik, MD†  
 Murat Seyit, MD†  
 Ali Kocycigit, MD‡  
 Mustafa Serinken, MD§

\* Acibadem University School of Medicine, Department of Emergency Medicine, Turkey  
 † Dumlupinar University, Department of Emergency Medicine, Turkey  
 ‡ Pamukkale University, Department of Radiology, Denizli, Turkey  
 § Pamukkale University, Department of Emergency Medicine, Turkey

Supervising Section Editor: Sean O. Henderson, MD

Submission history: Submitted March 28, 2014; Accepted April 18, 2014

Electronically published May 27, 2014

Full text available through open access at [http://escholarship.org/uc/uciem\\_westjem](http://escholarship.org/uc/uciem_westjem)

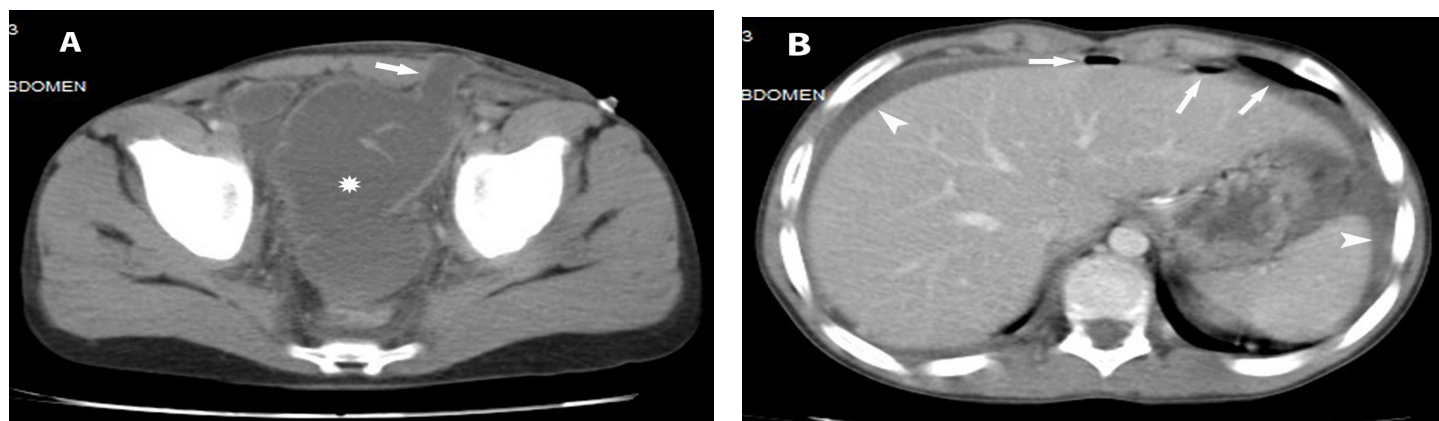
DOI: 10.5811/westjem.2014.4.22096

[West J Emerg Med. 2014;15(4):367–368.]

An 11-year-old boy was admitted to emergency department with abdominal pain, bilious vomiting and rectal bleeding one day after falling from bicycle. He stated that he landed directly onto the handlebar through his left lower quadrant of the abdomen. Physical examination revealed a soft tissue bulge, tenderness and defense in the left lower quadrant without any head or skeletal injury. His abdomen was soft with no evidence of peritoneal irritation. The patient's vital signs, radiographs and blood tests (hemoglobin, 14.4 g/dl; hematocrit, 43.0%; white blood cell count,  $6 \times 10^3/\text{mm}^3$ ; C-reactive protein, 10 mg/dl; Sodium (Na), 130 mmol/L) were within normal limits. Ultrasound demonstrated intra-abdominal fluid and herniation of a small bowel loop through the abdominal wall at left lower quadrant. Computed tomography (CT) of the abdomen revealed the herniation of jejunal loop through a defect in the left lower abdominal wall just lateral to the rectus muscle, segmental ileus due to the herniated bowel segment, intraperitoneal fluid and pneumoperitoneum (Figure). Based on these findings,

the patient was referred to pediatric surgery service with the diagnosis of intestinal perforation and abdominal wall hernia. Surgical exploration of the injured area demonstrated the disruption of all layers of the abdominal wall, and perforation of the jejunum at 110 cm distal to Trietz ligament. The postoperative period was uneventful.

Abdominal wall hernia and related visceral organ injuries should be considered following blunt abdominal trauma. In our case, high velocity impact by handlebar was able to disrupt abdominal muscle and fascia. In most handlebar hernias, the defect is in the lower abdominal wall and can be associated with intra-abdominal injury.<sup>1,2</sup> Injuries to the small bowel may occur secondary to high impact blunt trauma in a variety of deceleration mechanisms such as high-speed motor vehicle crashes, handlebar injuries, and falls.<sup>3</sup> Diagnosis is often delayed because there is usually no associated major blood loss. The small intestine is the most common site of perforation, and peritoneal irritation may not be evident initially. Plain radiograph is also unreliable



**Figure.** A. Axial computed tomography demonstrates the anterior abdominal wall defect and the herniated small bowel segment (arrow) with segmental ileus presented as dilatation of small bowel (\*). B. Pneumoperitoneum (arrows) and free peritoneal fluid around the liver and spleen (arrowheads).

in diagnosis.<sup>4</sup> CT is useful to differentiate hernia and its content, to define the anatomy of disrupted abdominal wall layers, and to detect associated injuries accurately and surgery is the eventual management of these patients.

---

*Address for Correspondence:* Mustafa Serinken, MD  
Pamukkale University, Department of Emergency Medicine,  
Denizli, Turkey. Email: mserinken@hotmail.com.

---

*Conflicts of Interest:* By the WestJEM article submission agreement, all authors are required to disclose all affiliations, funding sources and financial or management relationships

that could be perceived as potential sources of bias. The authors disclosed none.

#### REFERENCES

1. Offman RP, Spencer RM. Incarcerated diaphragmatic hernia with bowel perforation presenting as a tension pneumothorax. *West J Emerg Med.* 2014;15: 142-4.
2. Shiber J, Journey J. Traumatic Ventral Hernia: The Seat-Belt Sign. *J Emerg Med.* 2014;46(1):e19-20.
3. Goh SC, Welch C, Houlden CJ, et al. Traumatic bicycle handlebar hernia. *Eur J Emerg Med.* 2008; 15:179-180.
4. Lam JP, Eunson GJ, Munro FD, et al. Delayed presentation of handlebar injuries in children. *BMJ.* 2001; 322: 1288-1289.