

Point-of-Care Ultrasound to Locate Retained Intravenous Drug Needle in the Femoral Artery

Blake Primi, BA*
Molly E.W. Thiessen, MD*†

*University of Colorado School of Medicine, Department of Emergency Medicine, Aurora, Colorado

†Denver Health Medical Center, Department of Emergency Medicine, Denver, Colorado

Section Editor: Rick A. McPheeters, DO

Submission history: Submitted June 1, 2016; Revision received July 28, 2016; Accepted August 5, 2016

Electronically published September 12, 2016

Full text available through open access at http://escholarship.org/uc/uciem_westjem

DOI: 10.5811/westjem.2016.8.31074

We describe the use of point-of-care ultrasound to localize a retained intravenous drug needle, and subsequent surgical removal without computed tomography. [West J Emerg Med. 2016;17(6)817-8.]

CASE

A 33-year-old male presented to the emergency department (ED) with left groin pain. Six days prior, a needle had broken off in his groin while injecting intravenous (IV) drugs. On exam, he had track marks in his left groin, but no evidence of infection. The neurovascular exam of his left lower extremity was normal.

The patient had a point-of-care ultrasound (POCUS) initially, and subsequently a plain film of his left groin.

The POCUS of his left groin demonstrated a linear foreign body oriented horizontally through his superficial femoral artery and deep femoral artery, just distal to the bifurcation. (Video 1, Figure 1)

A plain radiograph confirmed these findings (Figure 2).

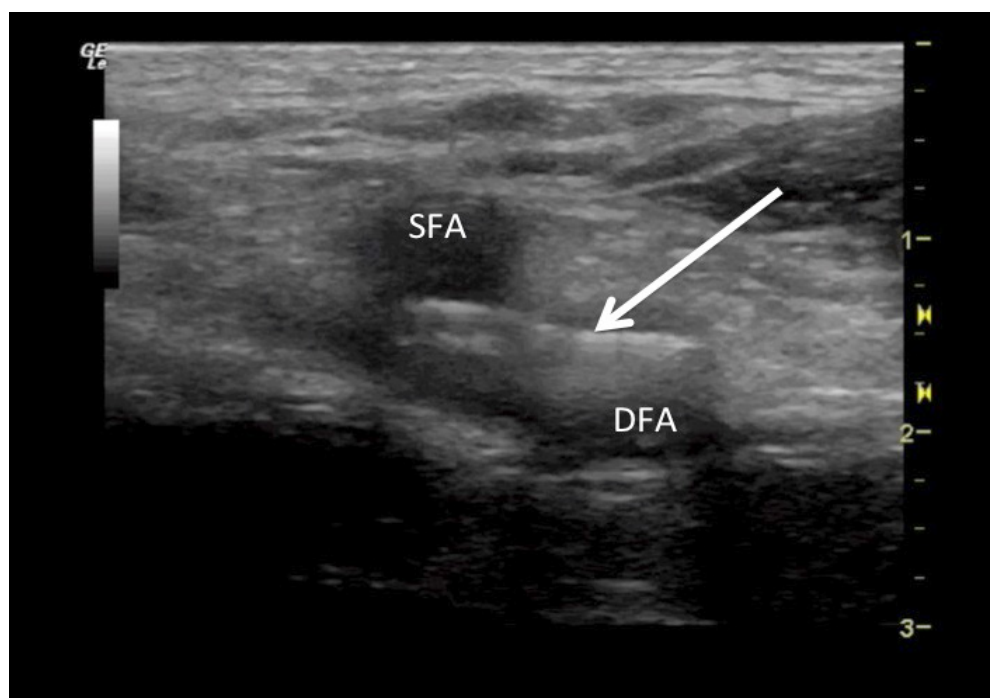


Figure 1. Linear foreign body (arrow) within the femoral artery just distal to the bifurcation of the superficial femoral artery (SFA) and the deep femoral artery (DFA), consistent with retained needle, as seen on point-of-care ultrasound.

The patient was taken from the ED to the operating room (OR) with no additional imaging. In the OR, the surgical team confirmed the presence of the foreign body with fluoroscopy, then dissected down to the femoral artery. Using the anatomic landmarks described in the POCUS, the surgery team localized and removed the needle. The patient was discharged later that morning.

DISCUSSION

Needle loss is not a rare occurrence for IV drug abusers.^{1,2} When dislodgement occurs in the vasculature, grave complications can ensue, as the needle has the potential to embolize to the right heart or lungs. Prompt extraction is

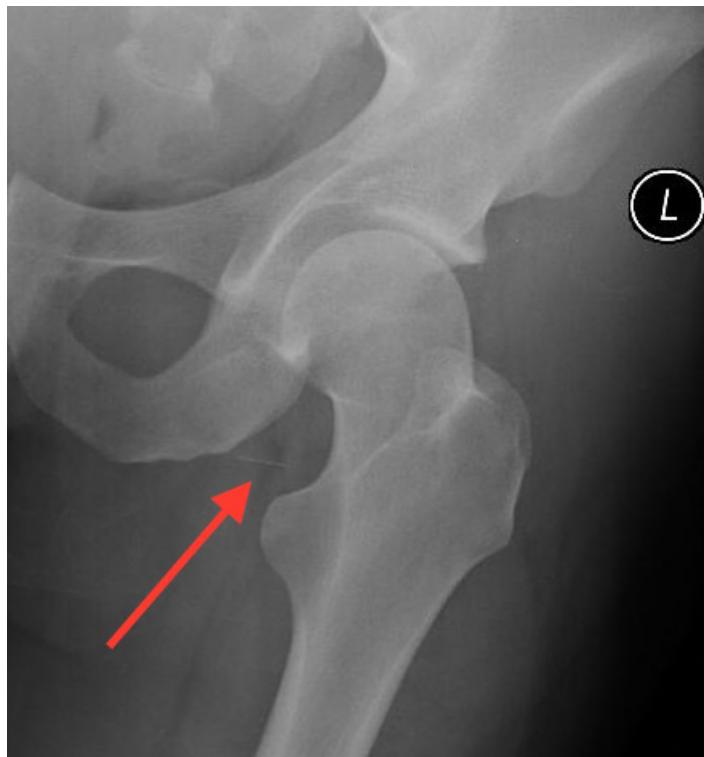


Figure 2. Linear foreign body (arrow) in the groin as seen on plain radiograph.

therefore necessary.^{3,4} Surgical extraction typically requires a pre-procedural computed tomography (CT) to localize the object.^{5,6} While effective, CTs are costly, expose the patient to considerably high doses of radiation, and lengthen the time to definitive treatment. Ultrasound is a well established method of locating radiolucent foreign bodies,^{7,8} with comparable efficacy in the detection of radiopaque foreign bodies in soft tissue when compared to CT.^{9,10} In cases of smaller wooden splinters, it has been found to be superior to CT.¹¹ In this case, we described the use of POCUS to localize a retained IV drug needle that was then surgically removed without complication, emphasizing the value of POCUS as a timely, cost-saving, radiation-sparing technology.

Video 1. Video of point-of-care ultrasound demonstrating the linear foreign body, consistent with retained needle, oriented horizontally just distal to the bifurcation of the superficial femoral artery (SFA) and the deep femoral artery (DFA).

Address for Correspondence: Molly E. W. Thiessen, MD, University of Colorado School of Medicine, Denver Health Medical Center, Department of Emergency Medicine, 777 Bannock Street, MC 0108, Denver, CO 80204. Email: Molly.Thiessen@dhha.org.

Conflicts of Interest: By the WestJEM article submission agreement, all authors are required to disclose all affiliations, funding sources and financial or management relationships that could be perceived as potential sources of bias. The authors disclosed none.

Copyright: © 2016 Primi et al. This is an open access article distributed in accordance with the terms of the Creative Commons Attribution (CC BY 4.0) License. See: <http://creativecommons.org/licenses/by/4.0/>

REFERENCES

- Williams MF, Eisele DW, Wyatt SH. Neck needle foreign bodies in intravenous drug abusers. *Laryngoscope*. 1993;103(1):59-63.
- Norfolk GA and Gray SF. Intravenous drug users and broken needles—a hidden risk? *Addiction*. 2003;98(8):1163-6.
- Monroe EJ, Tailor TD, McNeeley MF, et al. Needle embolism in intravenous drug abuse. *Radiol Case Rep*. 2012;7(3).
- Ngaage DL and Cowen ME. Right ventricular needle embolus in an injecting drug user: the need for early removal. *Emerg Med J*. 2001;18(6):500-1.
- Woodhouse JB and Uberoi R. Techniques for Intravascular Foreign Body Retrieval. *Cardiovasc Intervent Radiol*. 2012;36(4):888-97.
- Cahill AM, Ballah D, Hernandez P, et al. Percutaneous retrieval of intravascular venous foreign bodies in children. *Pediatr Radiol*. 2011;42(1):24-31.
- Ginsburg MJ, Ellis GL, Flom LL. Detection of soft-tissue foreign bodies by plain radiography, xerography, computed tomography, and ultrasonography. *Ann Emerg Med*. 1990;19(6):701-3.
- Turkcuer I, Atilla R, Topacoglu H, et al. Do we really need plain and soft-tissue radiographies to detect radiolucent foreign bodies in the ED? *Am J Emerg Med*. 2006;24(7):763-8.
- Oikarinen KS, Nieminen TM, Mäkäräinen H, et al. Visibility of foreign bodies in soft tissue in plain radiographs, computed tomography, magnetic resonance imaging, and ultrasound: An in vitro study. *Int J Oral Maxillofac Surg*. 1993;22(2):119-24.
- Aras MH, Miloglu O, Barutcuoglu C, et al. Comparison of the sensitivity for detecting foreign bodies among conventional plain radiography, computed tomography and ultrasonography. *Dentomaxillofacial Radiol*. 2010;39(2):72-8.
- Budhram, GR and Shmunk, JC. Bedside Ultrasound Aids Identification and Removal of Cutaneous Foreign Bodies: A Case Series. *J Emerg Med*. 2014;47(2):e43-8.